

Lawrence Parrish, John Mattson, Takanari Miyamoto, D. Roselyn Cerutis

Systemic azithromycin in the treatment of chronic periodontitis that persisted after non-surgical therapy. A report of two cases



Lawrence Parrish

Department of Periodontics
Creighton University School
of Dentistry
Omaha, Nebraska, USA

John Mattson

Department of Periodontics
Creighton University School
of Dentistry
Omaha, Nebraska, USA

Takanari Miyamoto

Department of Periodontics
Creighton University School
of Dentistry
Omaha, Nebraska, USA

D. Roselyn Cerutis

Department of Oral Biology
Creighton University School
of Dentistry
Omaha, Nebraska, USA

KEY WORDS *antibiotics, non-surgical periodontal therapy, periodontitis*

Chronic periodontitis is a bacteria-induced inflammatory process that results in signs of inflammation, including bleeding-on-probing and deepening probing depths. Treatment usually consists of oral hygiene instruction, root planing and possibly surgery. The present two case reports illustrate the use of the antibiotic azithromycin in the treatment of chronic periodontitis that persisted after scaling and root planing. In these cases, after re-evaluation at the completion of scaling and root planing, the patients elected not to have surgery, and instead decided to receive a course of azithromycin. The data demonstrated improvements in the signs of periodontal inflammation, and these improvements remained during several cycles of maintenance.

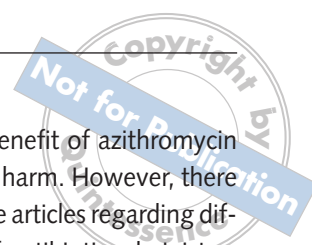
■ Introduction

Over the last 30 years, several articles in the literature have discussed the use of systemic antibiotics in the treatment of bacteria-induced inflammatory periodontal disease^{1,2,3,4,5}. The use of systemic antibiotics has been reported for both aggressive and chronic periodontitis. In their review, Walker and Karpinia³ stated that, when considering aggressive periodontitis, the selection of the antibiotic to be used was not standardised, although effectiveness had been reported for amoxicillin/clavulanic acid, clindamycin, metronidazole and the combination of metronidazole plus amoxicillin. According to a position paper on systemic antibiotics in periodon-

tics by the American Academy of Periodontology (AAP), antibiotic therapy may benefit those patients with aggressive types of periodontitis, or with medical conditions predisposing to periodontitis⁴. The report also noted that 'evidence exists suggesting that antibiotic use in chronic periodontitis may result in improvement in clinical attachment level, although many questions regarding the indications for this therapy remain unanswered'. The AAP report indicated that one advantage systemic antibiotics have over topical antibiotics is the ability to treat multiple periodontal sites of disease activity. In a systematic review, Haffajee et al⁵ found that 'the use of systemically administered adjunctive antibiotics with and without [scaling and root

Correspondence to:

Dr Lawrence Parrish
Creighton University School
of Dentistry
2500 California Plaza
Omaha, Nebraska 68178
USA
Tel: (402) 280-5039
Fax: (402) 280-5094
Email:
LawrenceParrish@creighton.
edu



planing] and/or surgery appeared to provide a greater clinical improvement in [attachment loss] than therapies not employing these agents'. The authors also noted that none of the antibiotics reviewed in their meta-analysis appeared to be superior to any other antibiotic.


In a comparison of four different periodontal therapies for chronic periodontitis, Haffajee et al⁶ found that sites with initially deep periodontal pockets showed significantly greater pocket depth reduction and attachment gain in subjects receiving metronidazole or azithromycin than in subjects receiving scaling and root planing (SRP) only, or SRP with doxycycline. In patients who smoked tobacco and who had moderate to severe periodontitis, Mascarenhas et al⁷ found that chronic periodontitis patients treated with SRP and azithromycin showed greater pocket depth reductions and gains in clinical attachment level than those who did not receive the antibiotic. Again, in relatively deeper probing depths (PDs), greater than 5.5 mm with clinical attachment loss, Smith et al⁸ found that the use of azithromycin led to fewer deep sites that failed to improve in PD, and fewer pockets continuing to bleed on probing when compared with the control group. Finally, Gomi et al⁹ found that patients with severe periodontitis, when prescribed azithromycin to be taken 3 days prior to SRP, demonstrated a statistically better outcome regarding average PDs, clinical attachment levels, bleeding-on-probing (BOP) and gingival crevicular fluid flow. Using a critical appraisal worksheet downloaded from the University of North Carolina (www.hsl.unc.edu/Services/Tutorials/ebd/AboutEBD.htm), a critical appraisal of the Mascarenhas⁷, Smith⁸ and Gomi⁹ articles revealed the following.

- With just a few reservations, the three studies appeared to have well-organised methodologies, the participants allocated and treated according to high standards, and the data collected and analysed appropriately.
- There are questions about the population sizes in both the Mascarenhas and Gomi articles, which lead to questions about the statistical significance in each case^{7,9}.
- Although both the Smith and Gomi articles had high precision in their analyses, Mascarenhas did not^{7,8,9}.

- In all of the articles, the benefit of azithromycin appeared to outweigh the harm. However, there is a lingering criticism of the articles regarding differences in the duration of antibiotic administration, and the cost effectiveness.

For the treatment of chronic periodontitis, azithromycin has compelling reasons for its use. Of all the macrolides, azithromycin has the best activity against the periodontopathogens *Actinobacillus actinomycetemcomitans* and *Porphyromonas gingivalis*¹⁰. Azithromycin concentrates in areas of inflammation, with it reportedly being 20% of maximum concentration by day 14 after a regimen of 500 mg once daily for 3 days in tissues that exhibited periodontitis^{11,12}. According to Voils et al, the anti-inflammatory properties of the macrolides include 'decreasing neutrophil chemotaxis, possibly by down-regulation of interleukin-6 (IL-6), IL-8, and tumour necrosis factor α , and they may have effects on the neutrophil oxidative burst and apoptosis'¹³. In comparison to the prescription regimens of other antibiotics, the use of azithromycin is conducive to patient compliance; Blumer proposed a rationale for the use of high-dose, short-course azithromycin treatment regimens, based on its long half-life and antibacterial potency¹⁴.

Based on the foregoing evidence-based research, over the past 4 years at a Creighton University School of Dentistry clinic, an azithromycin regimen was added to regimens of doxycycline and the combination of amoxicillin/metronidazole as adjuncts and options for aggressive periodontitis patients or for those chronic periodontitis patients who either were not candidates for periodontal surgery, or who refused to have surgery. Regimens of doxycycline and the combination of amoxicillin/metronidazole have been, and continue to be used by different practitioners at the clinic. However, the present report was focused retrospectively on the use of azithromycin. Before any data was compiled from patient records, approval from the institutional review board (IRB) was obtained (IRB # 06-14281, Creighton University). Out of all the patient records at the clinic, six patients were found who had received azithromycin for chronic periodontitis that persisted after non-surgical treatment. Out of those six, the following two cases have the most complete data and best represent the clinic's usage of azithromycin for chronic



periodontitis that persisted after non-surgical therapy, and the outcomes of that treatment. When considering the other four cases, data was incomplete, the patients moved away or the patient took other antibiotics during the reporting period for purposes other than periodontal reasons.

■ Case descriptions and results

■ Case 1

Medical and dental history and initial findings

A 34-year-old female presented to the Creighton University School of Dentistry clinic with triphasic birth control pills as her only current medication. She reported previous cigarette smoking at 1 pack per day for 10 years, but at the time of presentation, she stated that she was smoking only two to three cigarettes per day. Her dental history revealed that she brushed twice per day, but did not floss. Her initial Plaque Index (PI, O'Leary) was 78%, and the initial bleeding score was 100% of all PDs. Radiographic evaluation revealed signs of vertical bone loss at teeth at the mandibular left first and second molars, slight horizontal bone loss in the maxillary anterior sextant, and severe horizontal bone loss in the mandibular anterior sextant (representative radiographs in Fig 1). Degree I and II (Hamp, Lindhe and Nyman) furcation involvements were noted on the following teeth: maxillary right second molar, maxillary left first and second molars, mandibular left second molar, and mandibular right second molar. Class I (Miller) mobility was noted on the maxillary right central incisor, while the maxillary left central incisor, left first and second premolars, mandibular left second molar, mandibular right central incisor, and mandibular right second molar registered Class II mobilities. Open contacts were noted between the maxillary right lateral and right central incisors, the maxillary left central and left lateral incisors, the maxillary left lateral and left canine, the mandibular left canine and left lateral incisor, and the mandibular right first and second premolars. Orthodontic crowding was noted in the mandibular sextant. The gingiva appeared red, with blunted papillae and signs of oedema. PDs ranged from 2 mm to 8 mm, with 63 PDs in the 4 to 5 mm range and 25 PDs greater than 5 mm.

Periodontal diagnosis and treatment

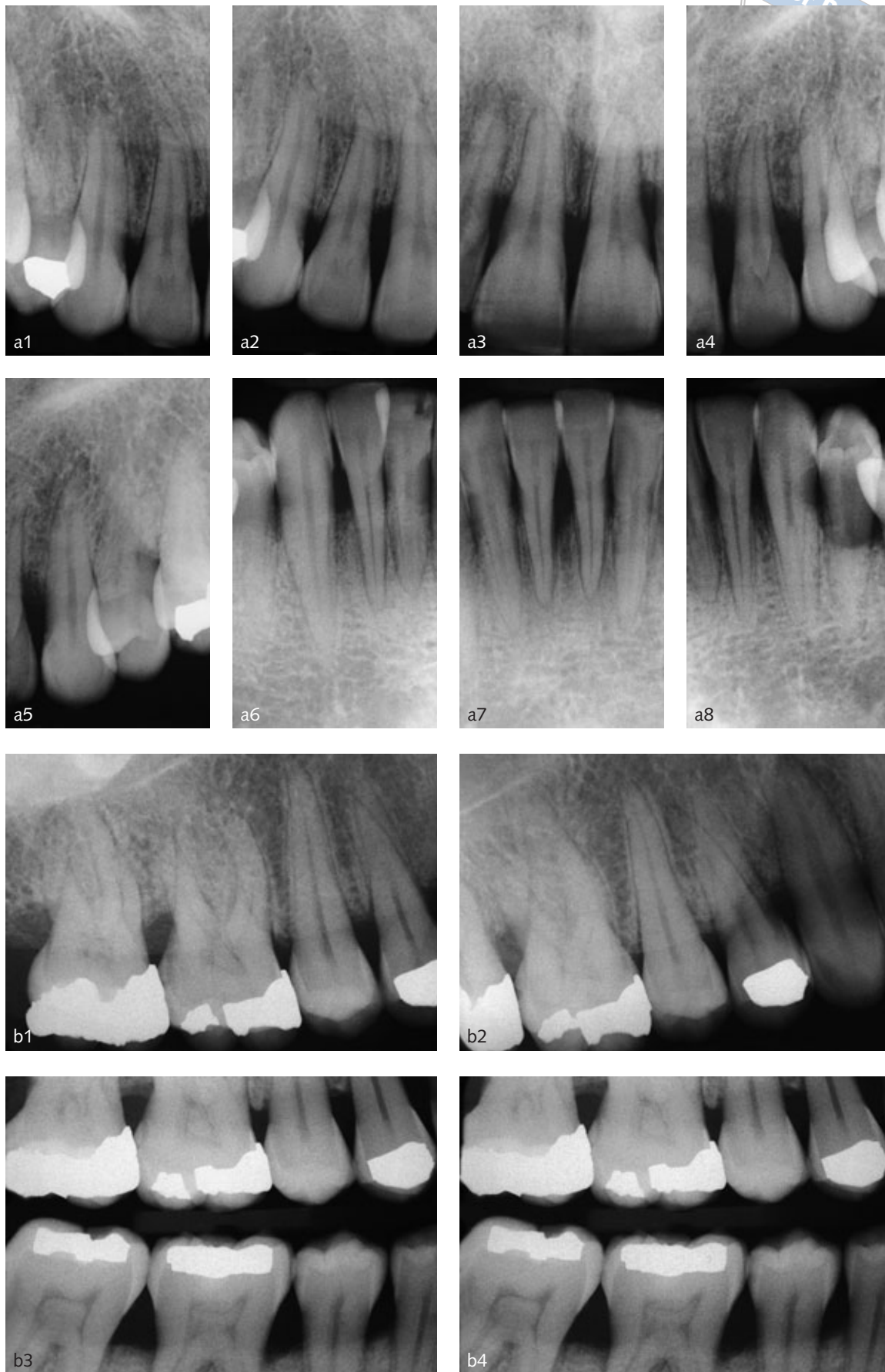
The periodontal diagnosis for case 1 was chronic generalised slight to severe periodontitis with secondary trauma from occlusion. The present study used the definition of trauma from occlusion as published in Carranza's *Clinical Periodontology*¹⁵. That is, trauma from occlusion occurs when occlusal forces exceed the adaptive capacity of the tissues. And, 'secondary trauma from occlusion occurs when the adaptive capacity of the tissues to withstand occlusal forces is impaired by bone loss resulting from marginal inflammation'¹⁵. The patient accepted a treatment plan that included non-surgical therapy (oral hygiene instruction, scaling and root planing, occlusal analysis and adjustment, and a 30-day re-evaluation after initial preparation). The patient was advised of the possible benefit from completely ceasing tobacco use, and the possibility of benefits from periodontal surgery if non-surgical therapy did not significantly improve signs of inflammation. The occlusal analysis revealed that the mandibular left second molar exhibited hyperocclusion in right lateral excursive movements of the mandible; the occlusion on the lingual aspects of the buccal cusps was slightly adjusted to reduce the horizontal forces on that tooth. The other teeth exhibiting trauma from occlusion were not found to have excessive horizontal forces being exerted on them.

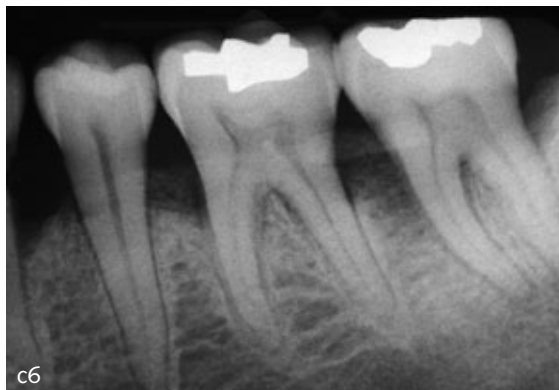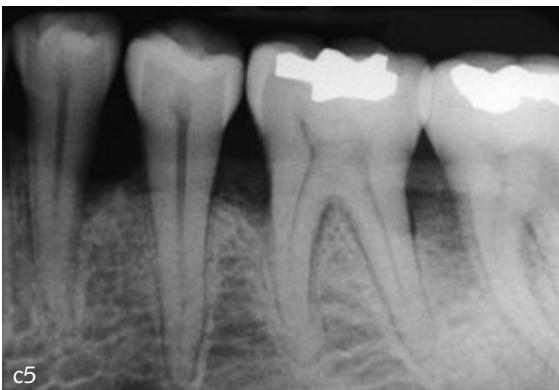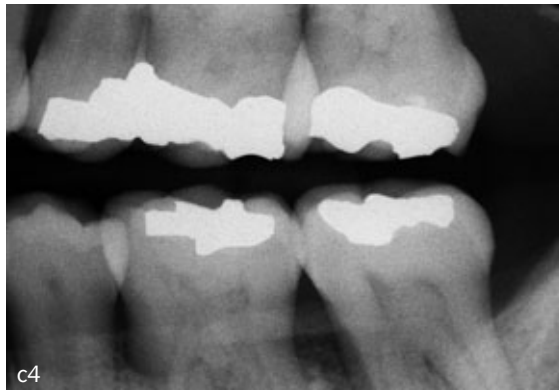
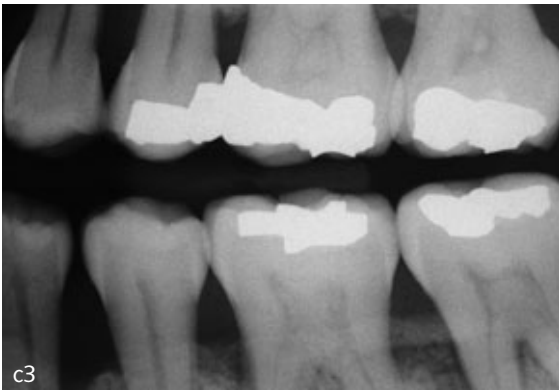
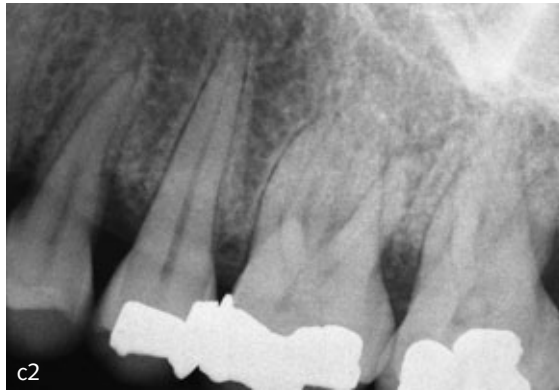
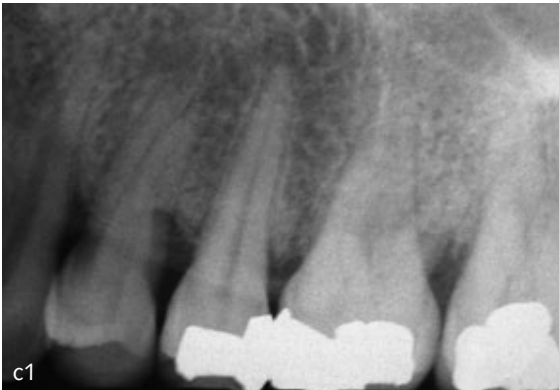
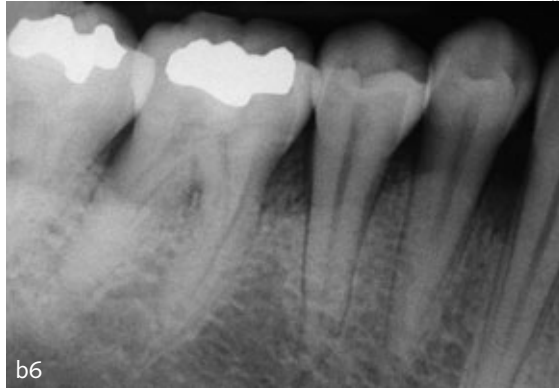
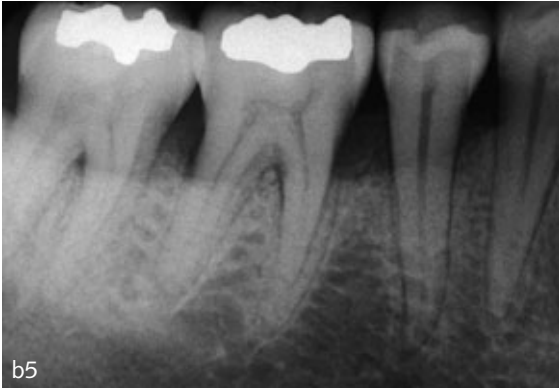After the completion of non-surgical therapy, re-evaluation at 3 months after the final root-planing appointment revealed that the bleeding score had changed from 100% to 62%, 40 PDs were 4 to 5 mm, while 31 PDs were greater than 5 mm. A total of 28 PDs decreased more than 1 mm, and 24 PDs increased more than 1 mm. The plaque index was 48%. The patient was given further oral hygiene instruction, including the modified Bass toothbrush technique and flossing. Although the patient was apprised of her condition, of the need for maintenance, and the option of surgery if she did completely cease using tobacco, she did not return for 17 months.


At the time that she did return, 38.7% of the PDs exhibited BOP, 27 of the PDs were between 4 and 5 mm, whereas 42 of the PDs were greater than 5 mm. Similar to the very first evaluation, selected teeth were found to have a range of mobility from Class I to Class III. The periodontal diagnosis was recurrent chronic slight to severe periodontitis, with



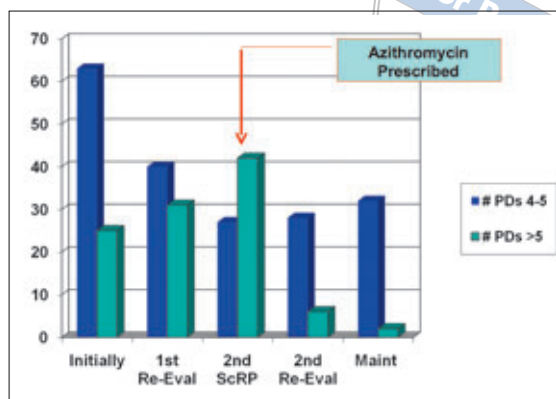
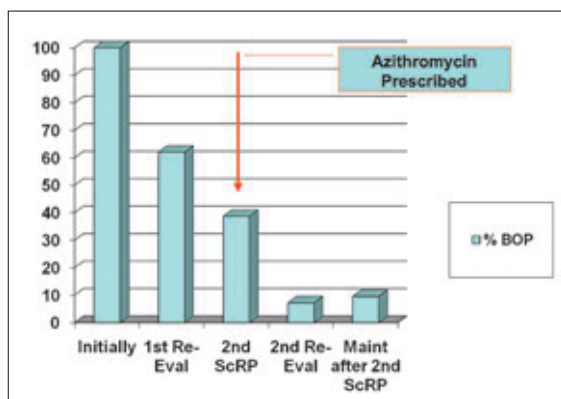
Fig 1 Case 1. Representative radiographs illustrating evidence of bone loss: a) anterior, b) right side and c) left side. The calculated clinical attachment loss, the existence of BOP, and the radiographic evidence of bone loss led to the diagnosis of periodontitis.







Figs 2 and 3 Case 1. After SRP, although BOP decreased, the percentage of sites exhibiting BOP was still above 30%, with a large number of PDs above 5 mm. After prescribing azithromycin, both the percentage BOP and number of deep PDs were significantly reduced.



Maint = maintenance; Re-eval = re-evaluation; SRP = scaling and root planing

trauma from occlusion. The patient was informed of the diagnosis. The patient stated that she was very reluctant to have surgery after any non-surgical treatment. The patient was informed of the possibility that a course of systemic antibiotic may be beneficial. She accepted a treatment plan that called for another course of non-surgical treatment, this time including an antibiotic course of systemic azithromycin. A prescription for six 250-mg tablets of azithromycin, two tablets every 12 hours the first day, and then one tablet every day thereafter. It should be noted that editions of the Drug Information Handbook for Dentistry from earlier in this decade did not specify a dosage for patients with periodontitis¹⁶. The online version now does list 500mg per day for 3 days as an appropriate daily dosing for chronic periodontitis. During the repeat non-surgical treatment, the patient exhibited a series of plaque index scores that began at 35%, and ended at 11%. Three months into the repeat non-surgical treatment phase, the patient announced that she had completely ceased tobacco use.

Periodontal re-evaluation took place at four months after the second non-surgical treatment. At that time, her bleeding score had changed from 38.7% to 7.14%, 28 of the PDs were between 4 and 5 mm, and 6 PDs were greater than 5 mm. A total of 59 PDs had decreased by greater than 1 mm, while 2 PDs had increased by greater than 1 mm. The patient was advised of the improvements in her signs of periodontal inflammation, and again advised of the need for maintenance, and the possible benefits of periodontal surgery.

At the first maintenance appointment, which occurred 3 months after her second re-evaluation,

and 7 months after the second course of root planing was initiated, her bleeding score was 9.5%, 32 PDs were between 4 and 5 mm, and 2 PDs were greater than 5 mm. Compared with the second re-evaluation, 10 PDs had decreased by greater than 1 mm, while 6 PDs had increased by greater than 1 mm.

For case 1, the sequential BOP percentage and PD data are graphically shown in Figs 2 and 3.

Case 2

Medical and dental history and initial findings

A 72-year-old female presented to the clinic with a medical history of sinus problems, 'minor arthritis in the left knee', and emotional issues. Her current medications included Effexor II, Topamax, fish oil, chondroitin/glucosamine triple strength, folic acid, multiple vitamin tablets, calcium and vitamin D, and biotin. Her physician managed tapering of Effexor II and she discontinued it within 12 months. Her initial PI was 12%. She stated that she brushed her teeth four to five times per day, and flossed at least once per day. The evaluation of her gingiva revealed signs of generalised inflammation with blunted papillae and enlarged gingiva especially in the posterior segments. The radiographic evaluation demonstrated vertical bone loss at the mandibular left first molar and right canine, with signs of generalised slight to moderate horizontal bone loss, especially in the mandibular anterior sextant (representative radiographs in Fig 4). The mandibular incisors demonstrated Miller Class I and II mobilities, and moderate malpositioning. There were 17.9% of the PDs exhibiting BOP, while 23 PDs were measured at 4 to 5 mm, and 27 PDs were greater than 5 mm (Figs 5 and 6). The patient was found to have restorative

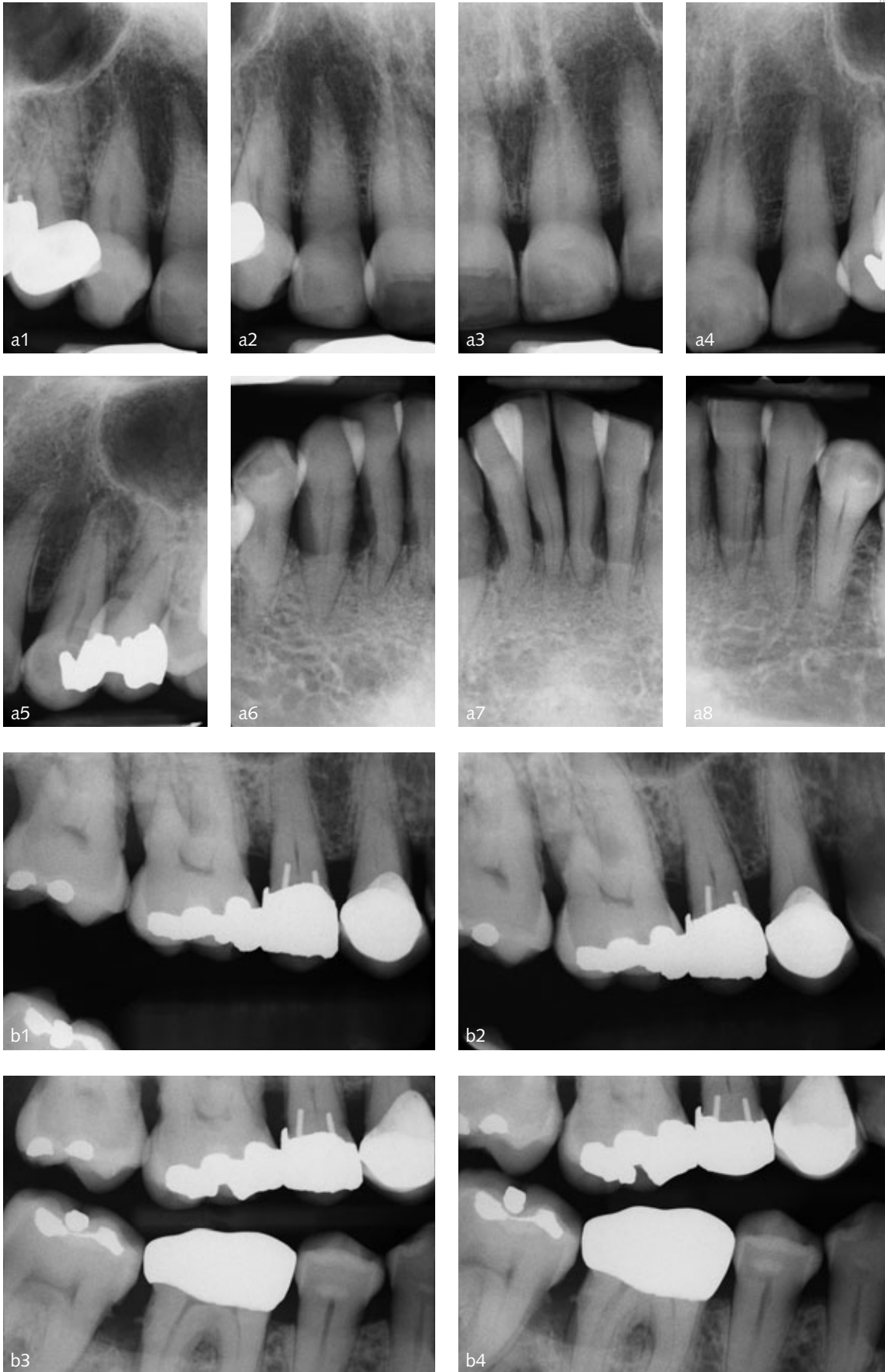

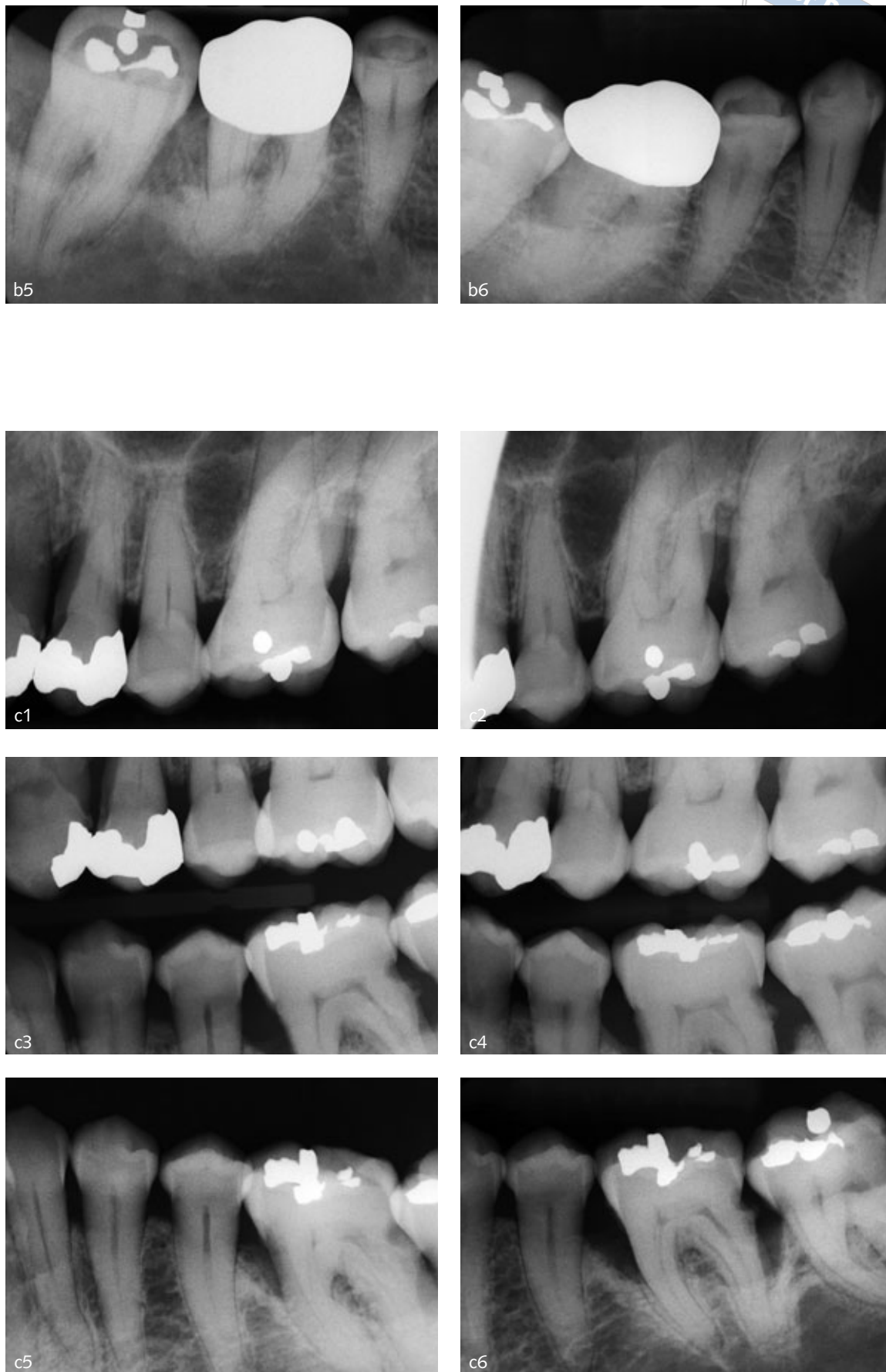
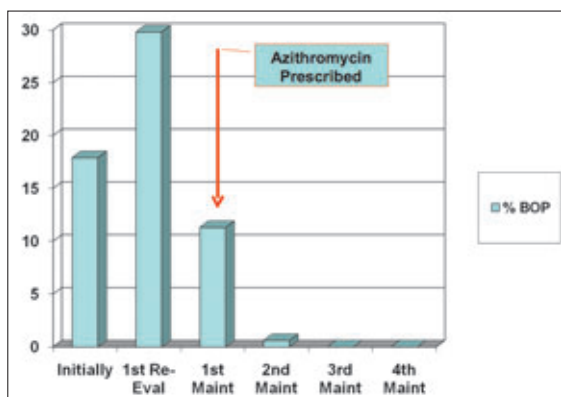


Fig 4 Case 2. Representative radiographs illustrating evidence of bone loss: a) anterior, b) right side and c) left side. The calculated clinical attachment loss, the existence of BOP, and the radiographic evidence of bone loss led to the diagnosis of periodontitis.

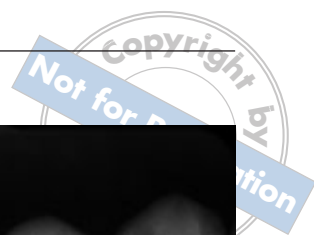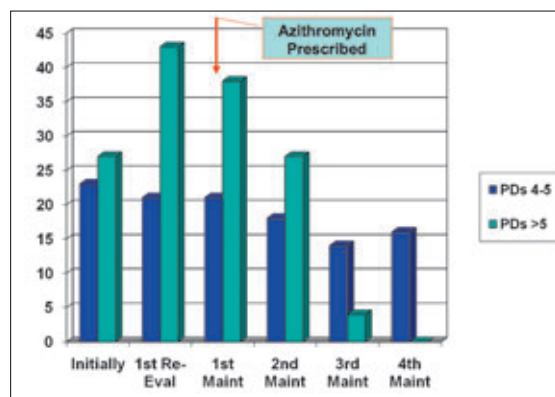


Fig 4 Case 2. Representative radiographs illustrating evidence of bone loss: a) anterior, b) right side and c) left side. The calculated clinical attachment loss, the existence of BOP, and the radiographic evidence of bone loss led to the diagnosis of periodontitis.





Maint = maintenance; Re-eval = re-evaluation



Figs 5 and 6 Case 2. At the re-evaluation after SRP, the percentage of BOP and the number of deep PDs actually increased. At the first maintenance appointment, azithromycin was prescribed, and thereafter the percentage of BOP and the number of deep PDs declined to zero.

and prosthodontic needs, and treatment was coordinated with other departments at the dental school.

Periodontal diagnosis and treatment

The diagnosis was chronic generalised slight to severe periodontitis, with an overall prognosis of fair to poor. The periodontal treatment plan included oral hygiene instruction, SRP, and a re-evaluation after initial preparation. The patient was informed of the possibility of benefit from periodontal surgery if her deep PDs did not respond optimally to non-surgical therapy.

At the periodontal re-evaluation appointment, which occurred 3 months after the final root planing, the patient exhibited a 15% PI, 29.8% of her PDs demonstrated BOP, 21 PDs measured 4 to 5 mm, and 43 PDs were greater than 5 mm. The patient was informed of the lack of improvement in her periodontal status, and periodontal surgery was suggested to the patient. The patient chose instead to enter a periodontal maintenance schedule, but was hampered by her family commitments.

At the first maintenance appointment, which occurred actually 5 months after the re-evaluation, the patient presented with 11.3% of PDs demonstrating BOP, 21 PDs were measured at 4 to 5 mm, and 38 PDs were over 5 mm. The patient was again informed of the potential benefits from periodontal surgery, but was also offered a course of azithromycin, which she accepted. The antibiotic was prescribed per the prescription stated for case 1. The importance of periodontal maintenance was also emphasised to the patient. At the second maintenance appointment one month later, 0.6% of the PDs exhibited BOP, while 18 PDs were measured at 4 to 5 mm, and 27 PDs were greater than 5 mm. Three months later at the third

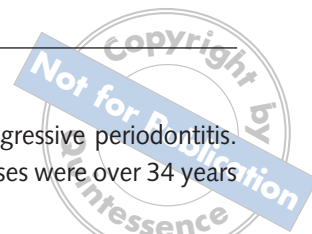
maintenance appointment, no PDs exhibited BOP. At the fourth maintenance appointment, which was 6 months after the third maintenance appointment, no PDs exhibited BOP, there were only 16 PDs ranging from 4 to 5 mm, and there were no PDs that were greater than 5 mm. At the fifth maintenance appointment, which was 6 months after the fourth maintenance appointment, no PDs exhibited BOP, there were no PDs in the 4 to 5 mm range, and there were no PDs that were greater than 5 mm.

For case 2, the sequential BOP percentage and PD data are graphically shown in Figs 5 and 6.

Discussion

In conjunction with mechanical removal of bacteria and bacterial toxins located on the root, it appears that the use of azithromycin in these two cases led to a reduction of BOP, and a trend toward fewer PDs that were greater than 5 mm. It did not totally eliminate those PDs ranging from 4 to 5 mm, as a portion of those PDs persisted after a course of the antibiotic. It also did not necessarily eliminate the recognised benefit from possible periodontal surgery, although the extent of any proposed surgery may have been diminished. Walker et al² noted that if systemic antibiotics are prescribed, such periodontitis cases which are refractory to standard treatment can remain stable for some time (in their report, 15 and 21 months), but that additional use of amoxicillin/potassium clavulanate may be necessary when signs of inflammation recur.

The treatment rendered at the Creighton University School of Dentistry clinic was thoroughly



assessed and refined by hygienists as well as general dentists and periodontists. Measures for assessing the adequacy of the interventions at each visit, especially the adequacy of the initial therapy, include standard assessment criteria of signs of inflammation (which include the BOP and PD data used in the present study), the PI, patient skills assessment and reinforcement, and the achievement of 'glassy-smooth' root surfaces. In both of the cases presented in this article, the patients had accomplished full-mouth SRP, and all root surfaces had achieved the 'glassy-smooth' endpoint.

The periodontists managing the two patients considered both of the cases as chronic periodontitis that had not responded to non-surgical therapy. A valid argument may be made that, particularly in case 1, since the patient had 'disappeared' for 17 months, another course of non-surgical therapy would have been in order before proceeding with a prescription of azithromycin. This viewpoint could be further reinforced by the fact that the PI remained rather high, and the patient could have benefited from further oral hygiene instruction and re-evaluation, prior to systemic antibiotic usage. Thus, another course of non-surgical therapy would have been a rational approach to case 1. It should be noted, however, that Smith et al⁸ did prescribe azithromycin to their experimental group at week 2 in their investigation. Also, if one is asking the question about single versus repeated instrumentation, Badersten et al¹⁷ found no improvement in outcomes if repeated instrumentation was accomplished at 3 month intervals for 3 cycles, and that this lack of difference persisted over a 24-month period. However, as Low pointed out in 2001¹⁸, Dr Badersten's patients exhibited better compliance, the PI history for her patients is not known and only non-molar teeth were included. Regarding the two patients in the present study, the periodontists managing the treatment of the patients at the time believed that the signs of periodontal inflammation and the treatment history justified offering the patients the option of the antibiotic at the respective points in time.


Neither of these cases could be classified as aggressive periodontitis. In both cases, the patients were known to have had chronic periodontitis for more than 2 years previous to time zero. Also, the distribution of attachment loss was not commensu-

rate with that of localised aggressive periodontitis. Finally, the patients in both cases were over 34 years of age.

Regarding case 1, there is some question as to the role of tobacco cessation in the course of the treatment. The use of cigarettes is known to be a contributory factor to chronic periodontitis^{19,20}. At the time of return, the amount of smoking ('one to two cigarettes per day') was significantly less than a rate of one or two packs per day. With the patient reducing her exposure to cigarette smoking by the time that she returned 17 months after initial root planing, it would be logical to assume that periodontal inflammation would improve. And to the extent that the BOP percentage had reduced, one could try to draw a conclusion that the combination of root planing and partial smoking cessation had brought about the decrease in inflammation. However, it is noted that the number of PDs of 4 to 5mm actually increased during that time. Thus, just a significant reduction in smoking cigarettes did not lead to a clear reduction in all signs of periodontal inflammation. There may be some question if systemic antibiotics would be effective in chronic periodontitis cases in which the patients are smokers. However, Mascarenhas⁷ et al reported the effectiveness of azithromycin in reducing PD and improving attachment levels in smokers with moderate to advanced attachment loss. Also, the local delivery of antimicrobials has been shown to be effective in treating periodontitis in smokers^{21,22}. In the present study, whether or not to use locally delivered antibiotics versus systemic antibiotics depends on the pervasiveness of PDs greater than or equal to 6mm with BOP.

The responses of the patients to azithromycin have been similar to the outcomes reported in experimental research by Haffajee et al⁶, Mascarenhas et al⁷ and Gomi et al⁹. In these articles, as well as in the present report, the deeper pockets appeared to be especially affected. In the present cases, the effect of antibiotic therapy on BOP lasted for a prolonged time (at least 10 to 15 months) throughout the initial observation period.

It should be noted that an additional 12 months has past (beyond the data listed in the bar graphs of Figs 2, 3, 5 and 6) for each of the cases reported here. The latest data are as follows: case 1, 9.5 % of PDs exhibited BOP, 17 PDs measured 4 to 5mm; and



1 PD measured greater than 5 mm; case 2, none of the PDs exhibited BOP; 15 PDs measured at 4 to 5 mm; and none of the PDs measured greater than 5 mm. Although a surgical approach may have been appropriate after non-surgical initial preparation, the fact that the two cases have not relapsed would support the hypothesis that surgery may not be necessary, or at least the extent of surgery may be minimized in some cases of chronic periodontitis.

Whether a surgical approach or an approach that incorporates azithromycin would be more beneficial in the long term depends on the patient's contributory factors and compliance. Researchers have shown long-term benefits of non-surgical therapy in maintaining clinical attachment levels, with and without systemic antibiotics^{23,24}. However, those long-term successes depend on optimal oral hygiene and regular maintenance visits for monitoring the status of the periodontium and reinforcement of daily plaque removal by the patient. If the patient does not take adequate responsibility for home care and other compliance issues, relapse is likely to occur. In the case of relapse, the exact criteria for repeat prescription of azithromycin has not been determined. Continued follow-up has been planned for cases that have received the antibiotic, in order to determine at what point in time relapse may occur, under what conditions and if another course of azithromycin would be beneficial.

References

- Gordon JM, Walker CB. Current status of systemic antibiotic usage in destructive periodontal disease. *J Periodontol* 1993;64:760-771.
- Walker CB, Gordon JM, Magnusson I, Clark WB. A role for antibiotics in the treatment of refractory periodontitis. *J Periodontol* 1993;64:772-781.
- Walker C, Karpinia K. Rationale for use of antibiotics in periodontics. *J Periodontol* 2002;73:1188-1196.
- Slots J; Research, Science and Therapy Committee. Systemic Antibiotics in Periodontics. *J Periodontol* 2004;75:1553-1565.
- Haffajee AD, Socransky SS, Gunsolley JC. Systemic anti-infective periodontal therapy. A systematic review. *Ann Periodontol* 2003;8:115-81.
- Haffajee AD, Torresyap G, Socransky SS. Clinical changes following four different periodontal therapies for the treatment of chronic periodontitis: 1 year results. *J Clin Periodontol* 2007;34:243-253.
- Mascarenhas P, Gapski R, Al-Shammari K, Hill R, Soehren S, Fenno JC, et al. Clinical response of azithromycin as an adjunct to non-surgical periodontal therapy in smokers. *J Periodontol* 2005;76:426-436.
- Smith SR, Foyle DM, Daniels J, Joyston-Bechal S, Smales FC, Sefton A, Williams J. A double-blind placebo-controlled trial of azithromycin as an adjunct to non-surgical treatment of periodontitis in adults: clinical results. *J Clin Periodontol* 2002;29:54-61.
- Gomi K, Yashima A, Nagano T, Kanazashi M, Maeda N, Arai T. Effects of full-mouth scaling and root planing in conjunction with systemically administered azithromycin. *J Periodontol* 2007;78:422-429.
- Yagiela JA. *Pharmacology and Therapeutics for Dentistry*, ed 5. St. Louis: Elsevier Science, 2004:639.
- Gomi K, Yashima A, Iino F, Kanazashi M, Nagano T, Shibukawa N, et al. Drug Concentration in Inflamed Periodontal Tissues After Systemically Administered Azithromycin. *J Periodontol* 2007;78:918-923.
- Blandizzi C, Malizia T, Lupetti A, Pesce D, Gabriele M, Giuca M R, et al. Periodontal tissue disposition of azithromycin in patients affected by chronic inflammatory periodontal diseases. *J Periodontol* 1999;70:960-966.
- Voils SA, Evans ME, Lane MT, Schosser RH, Rapp RP. Use of macrolides and tetracyclines for chronic inflammatory diseases. *Ann Pharmacother* 2005;39:86-94.
- Blumer JL. Evolution of a new drug formulation: the rationale for high-dose, short-course therapy with azithromycin. *Int J Antimicrob Agents* 2005;26(suppl 3):143-147.
- Carranza FA. Periodontal response to external forces. In: Newman M, Takei H, Klokkevold P, Carranza F. *Carranza's Clinical Periodontology*, ed 10. St. Louis: Saunders, 2006:467-474.
- Wynn RL, Meiller TF, Crossley HL. *Drug Information Handbook for Dentistry*, ed 8 (2003), ed 9 (2004), ed 10. Hudson, Ohio: Lexi-Comp, 2005.
- Badersten A, Nilveus R, Egelberg J. Effect of nonsurgical periodontal therapy III. Single versus repeated instrumentation. *J Clin Periodontol* 1984;11:114-124.
- Low SA. Clinical considerations in nonsurgical mechanical therapy. *Periodontol* 2000, 1995;9:23-26.
- Natto S, Baljoon M, Bergström J. Tobacco smoking and periodontal health in a Saudi Arabian population. *J Periodontol* 2005;76:1919-1926.
- The Research, Science and Therapy Committee of The American Academy of Periodontology. Position Paper: Tobacco Use and the Periodontal Patient. *J Periodontol* 1999;70:1419-1427.
- Williams RC, Paquette DW, Offenbacher S, Adams DF, Armistage GC, Bray K, et al. Treatment of periodontitis by local administration of minocycline microspheres: a controlled trial. *J Periodontol* 2001;72:1535-1544.
- Machion L, Carleto DA, Saito D, Klein MI, Gonçalves RB, Casati MZ, et al. Microbiological changes with the use of locally delivered doxycycline in the periodontal treatment of smokers. *J Periodontol* 2004;75:1600-1604.
- Ehmke B, Moter A, Beikler T, Milian E, Flemmig TF. Adjunctive Antimicrobial Therapy of Periodontitis: Long-Term Effects on Disease Progression and Oral Colonization. *J Periodontol* 2005;76:749-759.
- Svärdström B, Wennström JL. Periodontal Treatment Decisions for Molars: An Analysis of Influencing Factors and Long-Term Outcome. *J Periodontol* 2000;71:579-585.