



Frédéric Duffau

## Gingival enlargement originating from medication and tooth migration



**Frédéric Duffau**  
26 Avenue Kléber,  
75116 Paris  
France

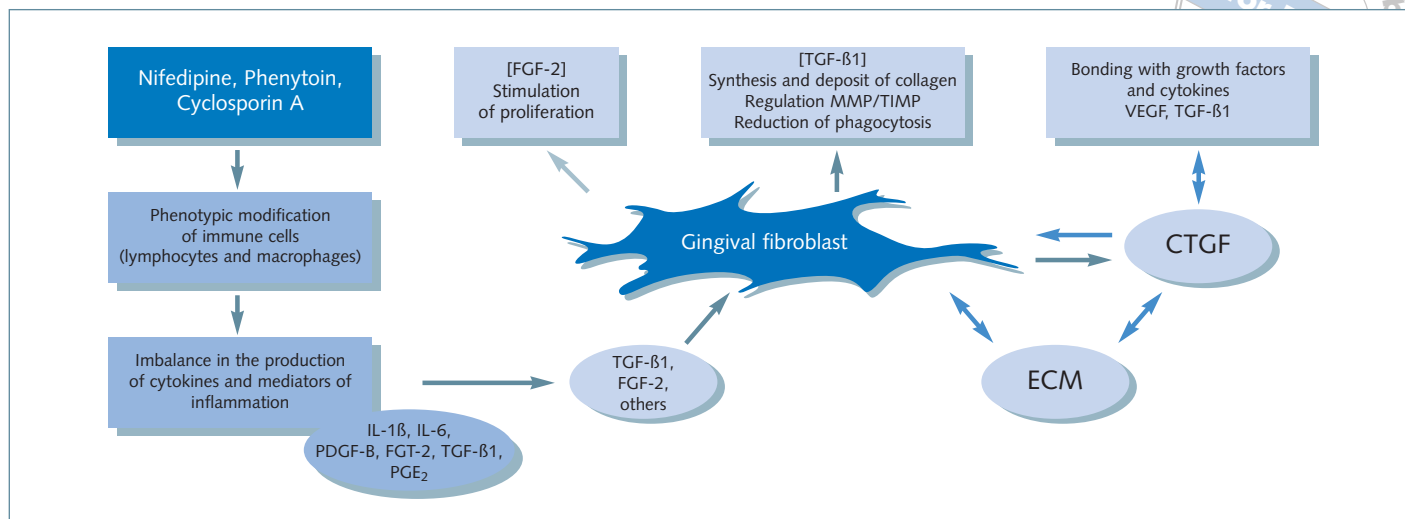
**KEY WORDS** *drug-induced gingival enlargement, gingival enlargement, medication, tooth migration*

Gingival enlargement can be a side effect of medication, including cyclosporin A, phenytoin and calcium channel blockers. This article discusses the mechanisms involved in gingival enlargement, illustrated with a case report. A 64-year-old female patient presented with tooth migration and gingival swelling. History revealed a previously similar situation after an increase in her dosage of Amlor<sup>®</sup>, a calcium inhibitor she had been prescribed for hypertension. The diagnosis was generalised chronic periodontitis associated with a gingival enlargement of medicinal origin. After treatment, the misaligned teeth spontaneously returned to alignment. The case illustrates that gingival enlargement can act not only as a bacterial trap, but also as a lever to move teeth.

Gingival enlargement can have various aetiologies. Some are hereditary, others are idiopathic and sometimes they can be associated with systemic diseases<sup>1</sup>. Less often, they have been observed among patients using cannabis<sup>2</sup>. The majority, however, are side effects of medication. Three families of drugs are involved in gingival enlargement: cyclosporin A (used in the treatment of organ transplants), phenytoin (used in the treatment of epilepsy) and calcium channel blockers (used in the treatment of arterial hypertension)<sup>1</sup>. The prevalence of these symptoms reached, in the best controlled studies, values of 30%

among transplant patients, 50% among epileptics and 6% with reference to calcium inhibitors<sup>3</sup>.

The term 'enlargement' has been preferred to those of 'hyperplasia' or 'hypertrophy', as used previously, because gingival enlargement results from more complex processes. Histologically, one can observe a hyperplasia of the epithelial junction, a hypertrophy of the keratinised epithelium and the presence of fibrous or dilated conjunctive tissue<sup>1</sup>. The events leading to gingival enlargement are complex. The most recent scientific data led to the theory of the mechanism described in Fig 1.



**Fig 1** Synthesis of the mechanisms, known and assumed, explaining gingival enlargement of medicinal origin. It is supposed that the concerned drugs cause deterioration of the phenotype of the immune cells, such as the lymphocytes and macrophages. This results in a disordered state of the cytokine balance and other mediators of the inflammation. It leads to a modification of the bacterial response to inflammation and trauma. Thus, a certain number of cytokines not only will re-orientate the synthesis of the extracellular matrix (ECM) by the gingival fibroblasts, but also will involve the proliferation of the latter. The modification of the fibroblastic metabolism, caused by the synthesis of transforming growth factor  $\beta$ 1 (TGF- $\beta$ 1), leads, for example, to the production of connective tissue growth factor (CTGF), which has a direct and indirect effect on the synthesis of the extracellular matrix and the activity of other growth factors and cytokines. The auto-provoked proliferation of the fibroblasts is explained by the synthesis of fibroblastic growth factor 2 (FGF-2). MMP/TIMP, matrix metalloproteinases/tissue inhibitors of metalloproteinases. Modified from Trackman and Kantarci<sup>1</sup>.

It has been established that the severity of gingival enlargement depends mainly on the accumulation of bacterial deposits on the dental surfaces<sup>3</sup>. Among certain patients, this enlargement can aggravate periodontal disease, first by contributing to the retention of dental plaque in the spaces ranging between the excess of gingival margins, the dental wall, and secondly by causing tooth migrations, which lead to obstructions and diastemas, thus reducing the effectiveness of brushing significantly.

The case of Mrs B. shows this clinical picture particularly well. This 64-year-old patient presented for a consultation, complaining of unsightly tooth migrations and swellings of the gum. During the interview, the patient remembered that gingival swellings had appeared 2 years earlier, following a dosage increase of Amlor<sup>®</sup> by her cardiologist, prescribed to reduce her hypertension. Amlor<sup>®</sup>, a calcium inhibitor of the dihydropyridins family, is not a drug generally selected for the study of gingival enlargement; however, it has been identified several times as an initiator of these symptoms.

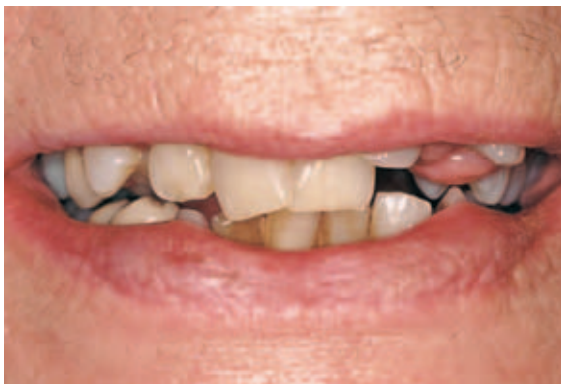Clinical examination showed a plaque index of 68.5%, a probing depth more than 4 mm in 44% of

the areas, bleeding on probing in 10% of the areas and suppurations on 37% of the teeth. Obvious dental migrations, associated with a noticeable gingival enlargement in all the sectors, led to a disharmony, as much functional as aesthetic (Figs 2 to 5).

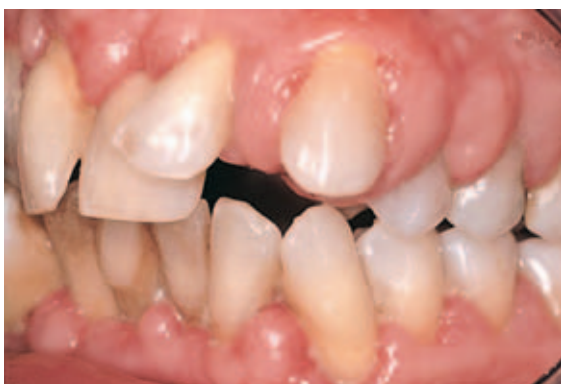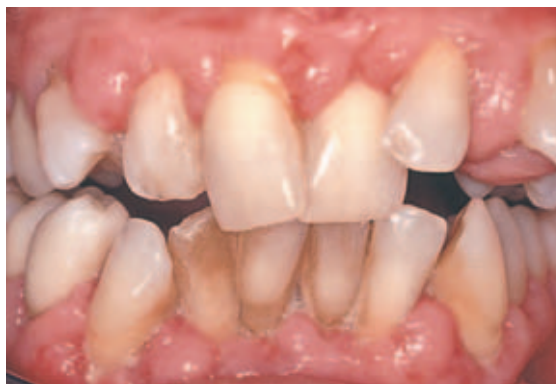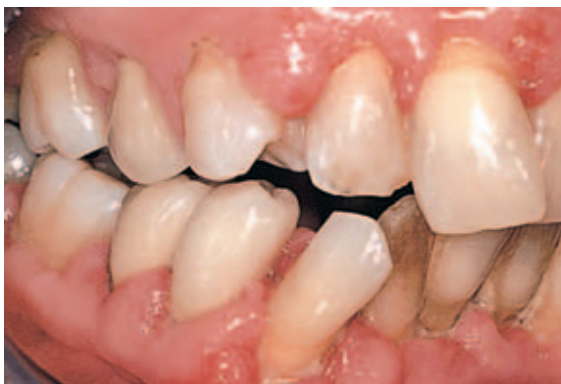The displacements of tooth 22 and 23 were the most noticeable (Fig 6). The increase was such that tooth 23 had been pushed into the vestibular until it had elevated the lip (Fig 2), and tooth 22 seemed to want to move towards the contralateral hemiarcade. Moreover, the lobular appearance of the papilla between tooth 22 and tooth 23 was particularly apparent when the patient smiled (Fig 2).

The retro-alveolar assessment revealed, from a periodontal view, a moderate to severe generalised alveolysis. The diagnosis was generalised chronic periodontitis associated with a gingival enlargement of medicinal origin.

The situation was explained to the patient and strict oral hygiene actions were established. During the month of summer vacation that followed, the patient was very conscientious in brushing all teeth, apart from 48, whose scheduled extraction had not yet been carried out. Consequently, a new enlargement developed between tooth 47 and tooth 48,



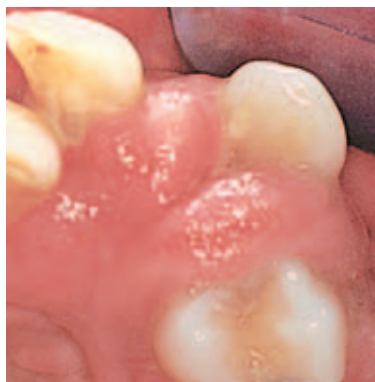**Fig 2** The patient's smile before treatment. The aesthetics are altered particularly by the apparent gingival enlargement in the area of tooth 22 and 23 and by the curve imposed on the lip by the vestibular migration of 23.



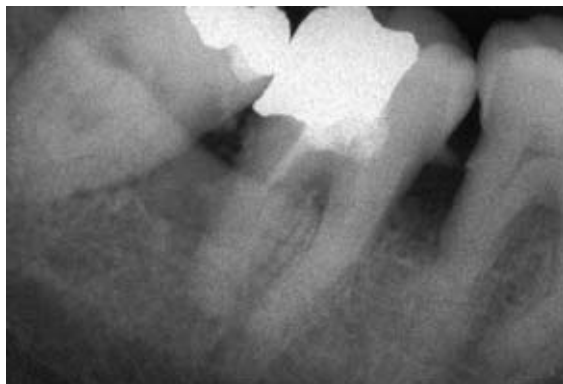
**Figs 3 to 5** Intraoral images before treatment.

pushing back the wisdom tooth by 2 mm distally (Figs 7 to 9).

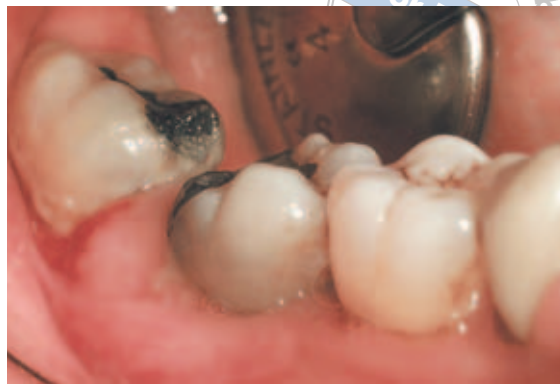Scaling and root planing sessions were scheduled, followed, after cicatrisation and stabilisation of the tissues, by periodontal surgery in all the sectors. Modified Widman flap procedures were carried out in the anterior region and full thickness flaps were repositioned apically in the posterior region. During these interventions, teeth 17, 27, 41 and 48 were extracted and the subsequent gingivectomies were realised in the sectors where the enlargements were most extensive.



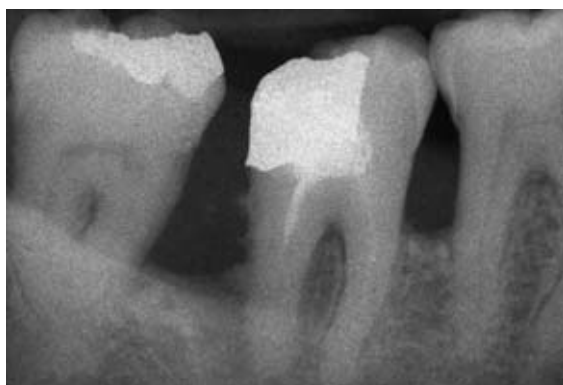**Fig 6** Occlusal view of the gingival increase around tooth 23, and of the secondary migrations of 22 and 23.



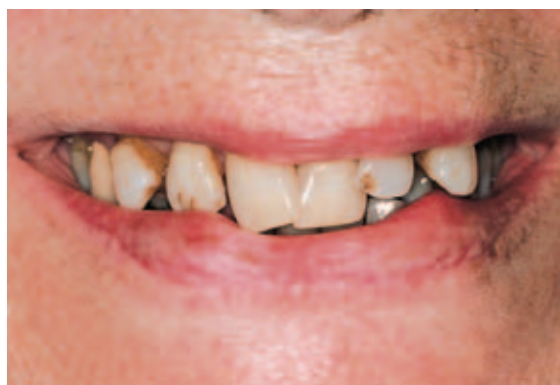**Fig 7** Initial retro-alveolar radiograph of tooth 47 and 48.



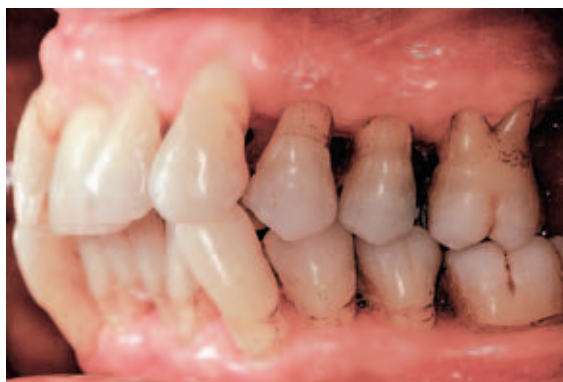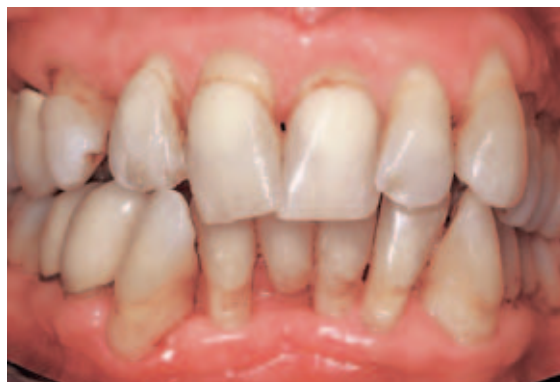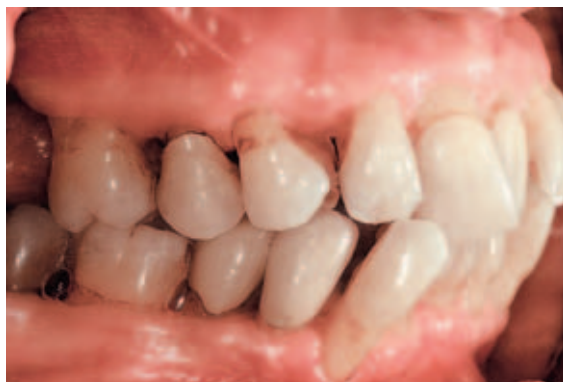**Fig 8** Vestibular view of the gingival enlargement that occurred, during treatment, between tooth 47 and 48, and of the secondary migration of tooth 48.




**Fig 9** Retro-alveolar radiograph of tooth 47 and 48, showing migration of tooth 48 in relation to the initial situation.



**Fig 10** The patient's smile after periodontal treatment. The papilla between tooth 22 and 23 is no longer visible and the return of tooth 23 to the arch reduces the labial curve.



**Figs 11 to 13** Intraoral images after periodontal treatment. The reduction in volume of the gingiva has enabled the natural closure of the diastemas. At this stage, orthodontic treatment nevertheless remains necessary to restore functionality, improve aesthetics and promote oral hygiene.



The closure of most of the diastemas was observed in the weeks following the interventions. Three months post-operatively, despite the cardiologist's insistence on using Amlor®, but thanks to excellent oral hygiene, no recurrence of gingival enlargement was observed; the tissue appeared healthy, and the secondary migrations were less noticeable (Figs 10 to 13).

The spontaneous return to alignment of tooth 22 and tooth 23 was reassuring, and made considerable improvement to the aesthetic and functional comfort of the patient possible. Orthodontic treatment is currently being implemented (Dr I Juzanx) to finish improving the interproximal connections and to facilitate the maintenance of good oral hygiene in the long term.

This case illustrates that gingival enlargement, in particular when it is of medicinal origin, not only is a 'bacterial trap', but also constitutes a powerful lever, able to move teeth, despite the balance being supposedly ensured by the labial musculature and occlusion. The inflammatory control and surgical elimina-

tion of persistent gingival enlargements are followed by the return to a situation close to that of the original.

The preservation of this situation requires conscientious compliance from the patient and the replacement, when possible, of the suspected drug with another, preferably of a different family.

## ■ References

1. Trackman PC, Kantarci A. Connective tissue metabolism and gingival overgrowth. *Crit Rev Oral Biol Med* 2004;15: 165–175.
2. Baddour HM, Audemorte TB, Layman FD. The occurrence of diffuse gingival hyperplasia in a patient using marijuana. *J Tenn Dent Assoc* 1984;64:39–43.
3. Dongari-Bagtzoglou A. Research, Science and Therapy Committee, American Academy of Periodontology. Drug-associated gingival enlargement. *J Periodontol* 2004;75: 1424–1431.

Originally published (in French) in *Titane* 2005; 2(3):15-17.