

Raquel RM Barros, Arthur B Novaes Jr, Daniela B Palioto,
Sérgio LS Souza, Mário Taba Jr, Márcio FM Grisi

A 36-month randomised controlled prospective clinical study of a conventional and a new surgical approach for root coverage with the acellular dermal matrix graft

KEY WORDS *acellular dermal matrix, randomised clinical study, root coverage*

Background: Long-term evaluation of gingival recession treatment is important for clinical decision-making. The aim of this clinical trial was to evaluate the acellular dermal matrix graft (ADMG) in the treatment of gingival recessions over a 3-year follow-up period, comparing a new surgical approach (test group) to a conventional procedure (control group).

Study design: A total of 28 bilateral Miller Class I or II gingival recessions were selected and randomly assigned to test and control groups. Gingival recession, width of keratinised tissue, probing depth and relative clinical attachment level were assessed at baseline, 12 months and 36 months post-surgery.

Results: Although both procedures improved all the evaluated parameters for all periods, comparisons between the groups revealed statistically significant greater recession reduction favouring the new technique from baseline to the 12-month evaluation and from baseline to the 36-month evaluation ($p = 0.000$). Statistically significant differences were not found between the 12-month and the 36-month evaluations; however, the root coverage obtained with the conventional technique decreased from 60% at 1 year to 58% at 3 years, while for the new technique it remained stable at approximately 83% over 3 years.

Conclusion: The new technique is more suitable for root coverage with ADMG when compared with the conventional procedure, showing a statistically significant better clinical performance that was maintained over a 3-year period.



Arthur B Novaes Jr
Chairman of Periodontology
and of the Department,
Faculdade de Odontologia
de Ribeirão Preto,
Universidade de São Paulo
Av. do Café, S/N,
14040-904,
Ribeirão Preto, SP, Brazil
E-mail: novaesjr@forp.usp.br

Raquel RM Barros
Graduate Student of
Periodontology,
School of Dentistry of
Ribeirão Preto,
University of São Paulo

Daniela B Palioto
Professor of Periodontology
School of Dentistry of
Ribeirão Preto,
University of São Paulo

Sérgio LS Souza
Professor of Periodontology
School of Dentistry of
Ribeirão Preto,
University of São Paulo

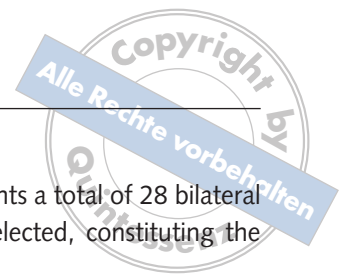
Mário Taba Jr
Professor of Periodontology
School of Dentistry of
Ribeirão Preto,
University of São Paulo

Márcio FM Grisi
Professor of Periodontology
School of Dentistry of
Ribeirão Preto,
University of São Paulo

■ Introduction

Long-term comparative evaluation of root coverage surgical procedures is important for clinical decision-making, because it provides information about the stability of results over several years¹.

Since its introduction in periodontics, the acellular dermal matrix graft (ADMG) has been successfully used as an advantageous substitute for the subepithelial connective tissue graft (SCTG) in the treatment of gingival recessions²⁻¹¹. Avoiding a second surgical site to harvest the autogenous con-



nective tissue donor material, the allograft decreases the risk of post-operative complications, and increases the number of teeth that can be treated in a single intervention. Similar good root coverage results were achieved with the SCTG and the ADMG procedures according to 6-month comparative clinical trials^{8,9} and 1-year comparative clinical trials^{11,12}. In addition, recently Hirsch et al¹³ showed that coverage of root by sub pedicle ADMG or SCTG is a very predictable procedure that is stable for 2 years post-operatively. However, it is important to emphasise that in these studies the allograft was used as an autogenous connective tissue graft through techniques that were primarily developed for the autograft. Considering that the ADMG has some unique characteristics, such as the absence of cells and the presence of vascular channels only that are not lined with endothelial cells, it can be suggested that a surgical technique, designed specifically for the allograft, may improve its performance and possibly obtain superior clinical results. In fact, a surgical technique designed for the treatment of localised gingival recessions with the ADMG was previously evaluated in a randomised clinical study in two post-operative periods, 6 and 12 months^{14,15}. This controlled study verified the superiority of this new surgical technique in comparison with the conventional technique, through statistically significant superior root coverage results in favour of the test procedure, in both 6- and 12-month evaluations.

Therefore, the purpose of the present study was to investigate the stability of these two different surgical techniques for the treatment of localised gingival recessions with the ADMG during a 36-month follow-up.

■ Study design

■ Study population

After the approval of the Institution's Human Research Committee, the patients selected for the study agreed to the study protocol and gave informed consent prior to treatment. The entry criteria were: 1) at least one pair of similar localised contralateral Miller Class I or II gingival recessions ≥ 3 mm; 2) no contributory medical history; and 3) non-smok-

ers. Under these requirements a total of 28 bilateral gingival recessions were selected, constituting the sample size.

After a plaque control programme, including oral hygiene instructions, scaling and root planing, and crown polishing, the selected bilateral gingival recessions were randomly assigned to test and control groups by the flip of a coin. Both groups were treated with the acellular dermal matrix (Alloderm, LifeCell, The Woodlands, TX, USA) as a subepithelial graft. In the control group the use of the allograft was based on a conventional technique proposed by Langer and Langer¹⁶ for the SCTG, but the graft was not left partially exposed as previously described. In the test group, the contralateral recessions were treated with the new technique and the allografts were also completely covered.

■ Clinical parameters

The clinical measurements – gingival recession (GR), probing depth (PD), relative clinical attachment level (RCAL), and width of keratinised tissue (KT) – were assessed by one blinded examiner at the mid-buccal point of the teeth with localised gingival recessions and their adjacent teeth using an automated periodontal probe (Florida Probe, Florida Probe Corporation, Gainesville, FL, USA) and an acrylic stent with reference marks to determine the exact site of measurement at the baseline, 12 months and 36 months after the surgeries. The width of keratinised tissue was assessed after staining the gingival tissues with Schiller's iodine solution.

■ Surgical procedures

The same operator performed the surgical procedures at the same clinical appointment. Following local anaesthesia, the flaps were designed to accommodate subepithelially the ADMG. In the control group the releasing incisions were placed on the proximal angles of the involved tooth (Fig 1) and in the test group the two releasing incisions were displaced to the mesial and distal line angles of the adjacent teeth, distant from the recession, providing a broader flap (Fig 2). Subsequently, the same steps were followed for both techniques. Sulcular incisions were made, uniting the releasing incisions, partial-

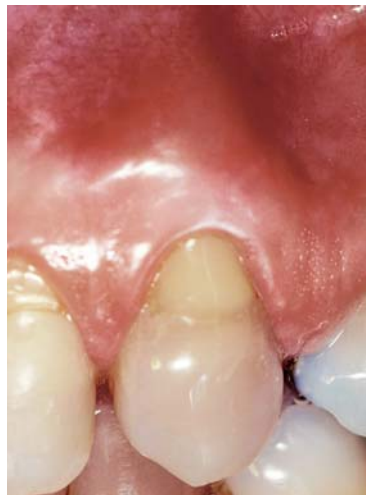

Fig 1a Pre-operative Miller Class I recession on a maxillary left canine.

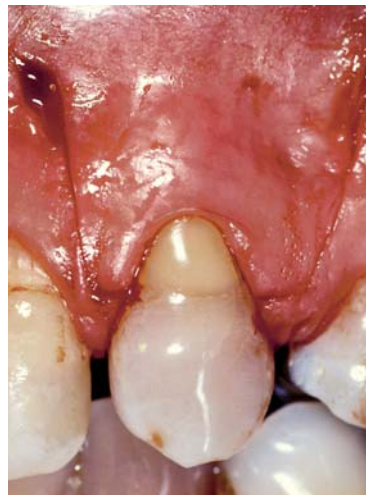

Fig 1b The releasing incisions at the proximal line angles of the involved tooth.

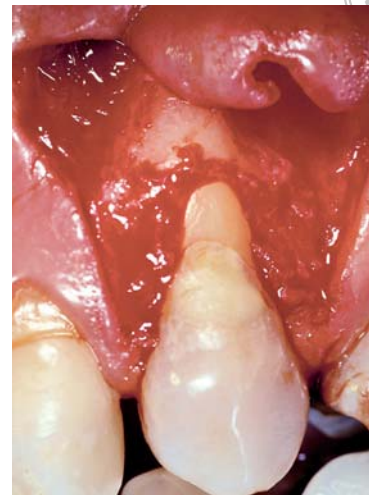


Fig 1c The partial-thickness flap reflected.

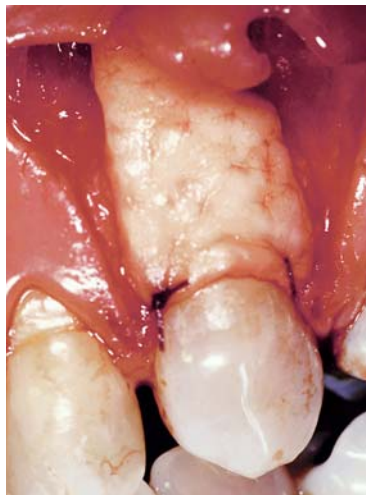

Fig 1d Acellular dermal matrix graft trimmed to the shape and size of the surgical bed and sutured in place.

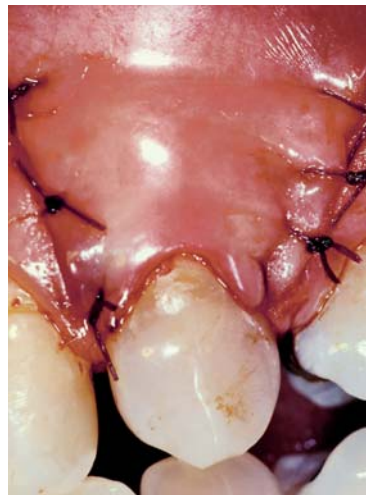

Fig 1e Flap coronally sutured to completely cover the graft.

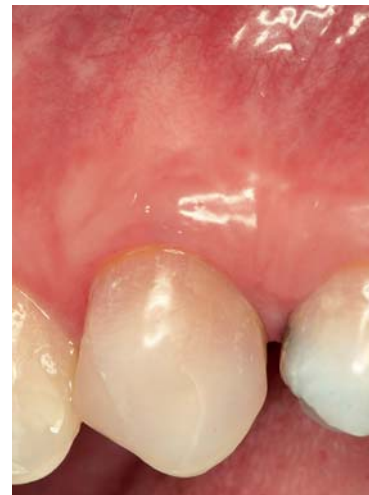

Fig 1f The treated area 36 months after surgery.

Fig 1 Surgical procedures in the control group, using conventional technique proposed by Langer and Langer¹⁶.

thickness flaps were reflected, and the exposed root surfaces were gently planed and conditioned with a 24% ethylenediaminetetraacetic acid (EDTA) gel preparation for 2 minutes with subsequent copious rinsing with sterile saline. Finally, the ADMGs were aseptically rehydrated in sterile saline, trimmed in shape and size in order to cover the exposed root surfaces and extending the distance of 2 mm laterally and sutured with sling 5-0 resorbable sutures. The previously reflected partial-thickness flaps were coronally positioned to entirely cover the allografts and also sutured into place with sling sutures. The areas were re-examined to ascertain that the allografts were completely covered and that the flaps were

sutured without tension. The vertical incisions were sutured with simple interrupted sutures. A periodontal dressing was applied, changed after 7 days, and removed after 14 days.

All patients were instructed to rinse 3 times a day with a 0.12% chlorhexidine digluconate solution for 14 days, and amoxicillin (500 mg, tid) was prescribed for 7 days, starting 24 hours before the surgical procedures. Discontinuation of tooth brushing and attention to avoid trauma or pressure at the surgical sites were also recommended during that period.

The sutures were removed after 14 days, and the patients were instructed to clean the surgical sites with a cotton pellet soaked in 0.12% chlorhexidine

Fig 2 Surgical procedures in the modified-technique group.

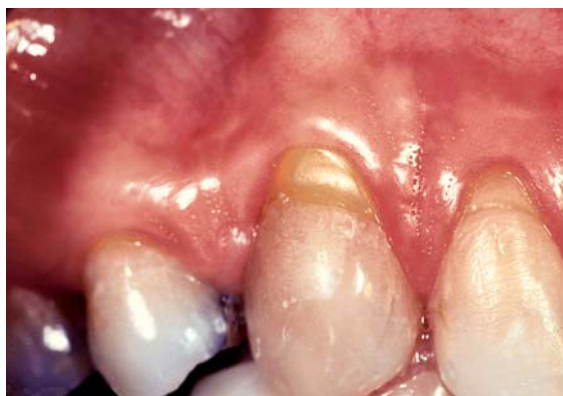

Fig 2a Preoperative Miller Class I recession on a maxillary right canine.

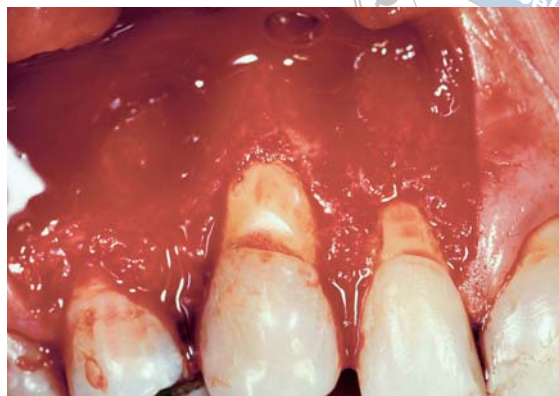

Fig 2b A partial-thickness flap reflected and delimited by the releasing incisions displaced to the proximal line angles of the adjacent teeth.

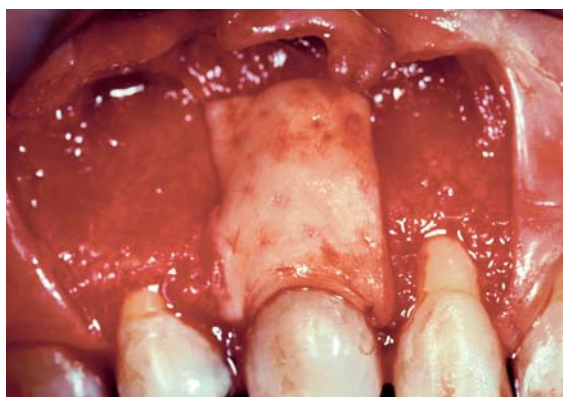

Fig 2c Acellular dermal matrix graft trimmed to the shape and size of the surgical bed and sutured over the defect of the tooth in question only.

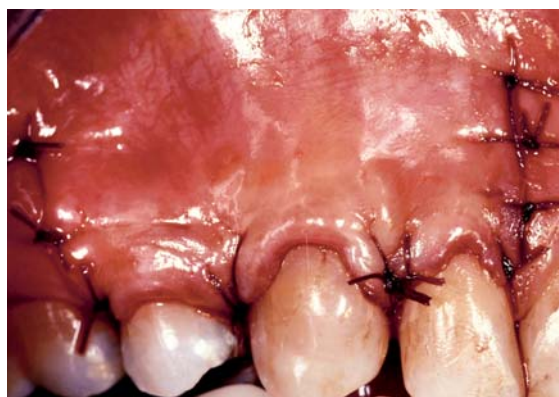

Fig 2d Flap coronally sutured to completely cover the graft.

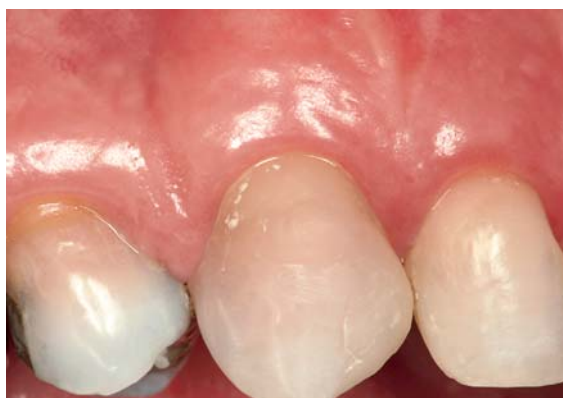

Fig 2e The treated area 36 months after surgery.

digluconate solution 3 times a day for more 10 days. The participants were recalled after the previously determined periods for clinical examinations and measurements, while maintenance procedures were performed at every 3 months.

■ Statistical analyses

Quantitative data were recorded as mean \pm standard deviation. The Mann-Whitney Test was used to determine if the two groups had similar-sized defects pre-operatively, and if one surgical procedure produced a better clinical result after 36 months. The Wilcoxon test was used to analyse if the clinical measurements differed before and after treatment. For all statistical analyses the significance level of 5% was adopted.

■ Results

Fourteen patients completed the 36-month evaluation, providing a total of 28 bilateral gingival recessions treated. Baseline dimensions of the defects were similar in both groups. Hence, the experimental groups were homogenous at baseline according to the

**Table 1** Mean values \pm SD (mm) of clinical parameters at baseline and 36-months examinations.

Parameter	Conventional technique			New technique			Between group difference**	
	12 months	36 months	Difference	12 months	36 months	Difference	12 months	36 months
GR	3.3 \pm 0.92	1.4 \pm 0.65	p = 0.001#	3.9 \pm 0.90	0.7 \pm 0.44	p = 0.001#	NS	p=0.000
KT	2.2 \pm 1.60	3.1 \pm 1.70	p = 0.006#	1.9 \pm 1.02	3.4 \pm 0.92	p = 0.002#	NS	NS
PD	1.6 \pm 0.53	1.4 \pm 0.48	NS#	1.6 \pm 0.54	1.1 \pm 0.34	p = 0.026#	NS	NS
RCAL	14.4 \pm 1.64	12.8 \pm 1.75	p = 0.003#	14.1 \pm 1.82	12.3 \pm 1.48	p = 0.002#	NS	NS

GR, gingival recession

KT, keratinised tissue width

PD, probing depth

RCAL, relative clinical attachment level

#, intra-group analysis – Wilcoxon Signed Ranks Test (significance level of 5%)

**, between group analysis – Mann Whitney U Test (significance level of 5%)

NS, no significant difference

Table 2 Mean changes \pm SD (mm) of clinical parameters between baseline and 36-months examinations within experimental groups.

Group	Parameter			
	GR	KT	PD	RCAL
Conventional technique	2.1 \pm 0.85	0.9 \pm 0.85	0.2 \pm 0.67	1.6 \pm 1.27
New technique	3.3 \pm 0.86	1.5 \pm 0.77	0.5 \pm 0.71	1.9 \pm 1.46
Difference**	p = 0.000	NS	NS	NS

Table 3 Mean values \pm SD (mm) of clinical parameters at 12- and 36-months examinations.

Parameter	Conventional technique			New technique			Between group difference**	
	12 months	36 months	Difference	12 months	36 months	Difference	12 months	36 months
GR	1.3 \pm 0.64	1.4 \pm 0.65	NS#	0.7 \pm 0.59	0.7 \pm 0.45	NS#	p=0.000	p=0.000
KT	3.2 \pm 1.65	3.1 \pm 1.70	NS#	3.2 \pm 0.93	3.4 \pm 0.92	NS#	NS	NS
PD	1.3 \pm 0.56	1.4 \pm 0.48	NS#	0.9 \pm 0.43	1.1 \pm 0.34	NS#	NS	NS
RCAL	12.8 \pm 1.77	12.8 \pm 1.75	NS#	12.3 \pm 1.55	12.5 \pm 1.49	NS#	NS	NS

GR, gingival recession

KT, keratinised tissue width

PD, probing depth

RCAL, relative clinical attachment level

#, intra-group analysis – Wilcoxon Signed Ranks Test (significance level of 5%)

**, between group analysis – Mann Whitney U Test (significance level of 5%)

NS, no significant difference

clinical parameters evaluated. Within each group, all the parameters showed significant improvement after 36 months (Table 1). The only exception was the PD reduction, which was not statistically different after this period in the control group.

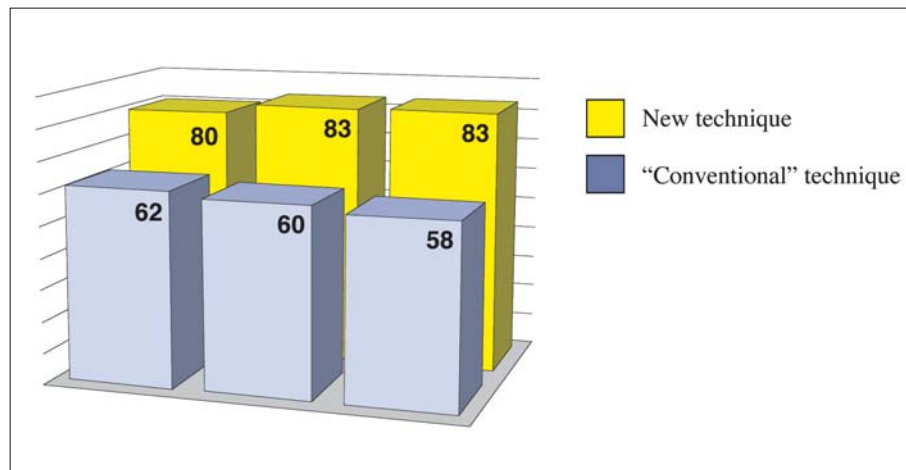
After 36 months, supporting the findings achieved in the previous 6-month and 12-month examinations, the gingival recession reduction of the test group was superior to that obtained in the control group and this difference was again statis-

tically significant (p = 0.000) (Table 2). Statistically significant differences were not found between the 12-month and the 36-month evaluations (Table 3), however the root coverage obtained with the conventional technique decreased from 60% at 1 year to 58% at 3 years, while for the new technique it remained stable around 83% over 3 years (Fig. 3).

With respect to the other parameters – increase in KT width, PD reduction and RCAL gain – no statistically significant differences were found between

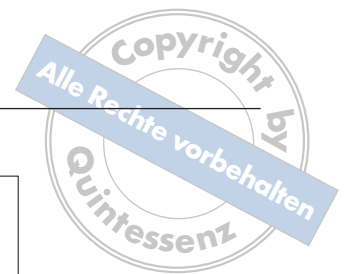

Fig 3 Root coverage (%) after 6, 12 and 36 months.



the groups after 36 months, although the improvements provided by the new technique were numerically greater than that obtained by the control group (Table 2).

Considering that the flap design of the new technique involves the adjacent teeth, these units of test and control groups were also evaluated during the study using the same parameters used for the selected teeth. In some cases these adjacent teeth were also affected by gingival recessions. Both procedures improved in some extent the parameters evaluated at the 36-month examination, however, the analysis between the two groups showed statistically significant changes in GR, width of KT and RCAL in favour of the test procedure.

■ Discussion

Initially, the objective of this controlled randomised prospective clinical study was to evaluate if a surgical technique designed specifically for the allograft could improve its performance and possibly obtain superior clinical results. Past 36 months, the focus of the present evaluation was to investigate the stability of results provided by the root coverage ADMG surgical techniques: the new surgical approach and the conventional procedure.

In the 6-month and 12-month evaluations^{14,15}, it was concluded that an extended flap (new technique) is more suitable for the treatment of localised gingival recessions with the ADMG when compared with the conventional SCTG flap design. It was discussed that the new surgical approach fulfils the allograft's extra vascular supply requirement. It is impor-

tant to emphasise that the ADMG is obtained from a human donor skin tissue process that removes its cell components while preserving the remaining bioactive components and the extracellular matrix. During this process only the collagen and elastin matrices are maintained undamaged to function as a scaffold to allow ingrowth by host tissues⁴. Therefore, the allograft retains a non-vital structure that depends on cells and blood vessels from the recipient site to achieve reorganisation⁴. In contrast, the healing and revascularisation of an autograft is also based on the anastomoses between blood vessels of the gingival corium and those pre-existing in the graft^{17,18}.

Considering that the survival capability of grafts at the receptor site represents a crucial point for gingival recession treatment success, the superior root coverage obtained with the test procedure in the previous 6-month and 12-month evaluations^{14,15} and also in the present 36-month evaluation could be explained by the disposal of an extra source of cells and blood vessels. According to Mörmann and Ciancio¹⁹, who investigated the changes in microcirculation of different surgical incisions and flaps in a fluorescein angiographic clinical study, the flaps should be broad enough at their base to include major gingival vessels. The new technique for root coverage with ADMG described in this study is based on the displacement of the releasing incisions to the proximal line angles of the adjacent teeth in order to favour the incorporation process of the allograft. This was achieved, not only providing more blood vessels, more nutrients and a better source of cells, but also allowing easier tissue manipulation, especially in



obtaining a tensionless coronally positioned flap to completely cover the allograft. This effort is particularly important, because the ADMG has the ability to revascularise only when in direct contact with vital tissues. Finally, the placement of the releasing incisions far away from the allograft also reduces the possibility of its exposure when compared with the conventional procedure, an important factor since it could compromise the root coverage.

In reference to the long-term evaluation of the present study, statistically significant differences were not found between the 12-month and the 36-month evaluations. However, the root coverage obtained with the conventional technique slightly decreased from 60% at 1 year to 58% at 3 years, while for the new technique it remained stable at approximately 83% over 3 years (Fig 3). This result indicates that an adequate surgical procedure for the ADMG is important not only to achieve improved root coverage but also to achieve stable long-lasting results in the treatment of gingival recessions.

The adjacent teeth of both groups were also evaluated during the study in order to verify if the inclusion of these teeth in the flap design of the new technique could be detrimental to them. However, the results showed that the test technique provided statistically significant improvements in the adjacent teeth in terms of GR reduction, increase in KT and gain in CAL from baseline to the 36-month examination when compared with the control group, probably as a result of the coronal displacement of the flaps.

■ Conclusions

The results of this study support the superiority of the new technique in the treatment of localised gingival recessions with ADMG when compared with the conventional procedure. The better clinical performance of the test procedure, statistically significant, was maintained over a 3-year period.

■ References

- Wennström JL. Mucogingival therapy. *Ann Periodontol* 1996;1:671–701.
- Silverstein LH, Callan DP. An acellular dermal matrix allograft substitute for palatal donor tissue. *Postgrad Dent* 1996;3:14–21.
- Schulman J. Clinical evolution of an acellular dermal allograft for increasing the zone of attached gingival. *Pract Periodontics Aesthet Dent* 1996;8:201–208.
- Batista Jr EL, Batista FC, Novaes Jr AB. Management of soft tissue ridge deformities with acellular dermal matrix. Clinical approach and outcome after 6 months of treatment. *J Periodontol* 2001;72:265–273.
- Harris RJ. Root coverage with a connective tissue with partial thickness double pedicle and an acellular dermal matrix graft: a clinical and histological evaluation of a case report. *J Periodontol* 1998;69:1305–1311.
- Dodge JR, Henderson R, Greenwell H. Root coverage without a palatal donor site, using an acellular dermal graft. *Periodont Insights* 1998;5:5–9.
- Tal H. Subgingival acellular dermal matrix allograft for the treatment of gingival recession: A case report. *J Periodontol* 1999;70:1118–1124.
- Aichelmann-Reidy ME, Yukna RA, Evans GH, Nasr HF, Mayer ET. Clinical evaluation of acellular allograft dermis for the treatment of human gingival recession. *J Periodontol* 2001;72:998–1005.
- Novaes Jr AB, Grisi DC, Molina GO, Souza SLS, Taba Jr M, Grisi MFM. Comparative 6-month clinical study of a subepithelial connective tissue graft and acellular dermal matrix graft for the treatment of gingival recession. *J Periodontol* 2001;72:1477–1484.
- Harris RJ. A comparative study of root coverage obtained with an acellular dermal matrix versus a connective tissue graft: results of 107 recession defects in 50 consecutively treated patients. *Int J Periodontics Restorative Dent* 2000;20:51–59.
- Tal H, Moses O, Zohar R, Meir H, Nemcovsky C. Root coverage of advanced gingival recession: a comparative study between acellular dermal matrix allograft and subepithelial connective tissue grafts. *J Periodontol* 2002;73:1405–1411.
- Paolantonio M, Dolci M, Esposito P, D'Archivio D, Lisanti L, Di Luccio A, Perinetti G. Subpedicle acellular dermal matrix graft and autogenous connective tissue graft in the treatment of gingival recessions: a comparative 1-year clinical study. *J Periodontol* 2002;73:1299–1307.
- Hirsch A, Goldstein M, Goultschin J, Boyan BD, Schwartz Z. A 2-year follow-up of root coverage using sub-pedicle acellular dermal matrix allografts and subepithelial connective tissue autografts. *J Periodontol* 2005;76:323–328.
- Barros RRM, Novaes Jr AB, Grisi MFM, Souza SLS, Taba Jr M, Palioto DB. A 6-month comparative clinical study of a conventional and a new surgical approach for root coverage with acellular dermal matrix. *J Periodontol* 2004;75:1350–1356.
- Barros RRM, Novaes Jr AB, Grisi MFM, Souza SLS, Taba Jr M, Palioto DB. A new surgical approach for root coverage of localized gingival recession with acellular dermal matrix: a 12-month comparative clinical study. *J Esthet Restor Dent* 2005;17:156–164.
- Langer B, Langer L. Subepithelial connective tissue graft technique for root coverage. *J Periodontol* 1985;56:715–720.
- Oliver RC, Löe H, Karring T. Microscopic evaluation of the healing and revascularization of the gingival grafts. *J Periodont Res* 1968;3:84–95.
- Janson WA, Ruben MP, Kramer GM, Bloom AA, Turner H. Development of the blood supply to split-thickness free gingival autografts. *J Periodontol* 1969;39:707–716.
- Mörmann W, Ciancio SG. Blood supply of human gingival following periodontal surgery. A fluorescein angiographic study. *J Periodontol* 1977;48:681–692.