

# Multiple or Disseminated Pyogenic Granulomata? A Complex Presentation in a Nine-Year-Old Boy

Mike R Milward, Nagui El-Shimy, Anthony Roberts, Iain LC Chapple

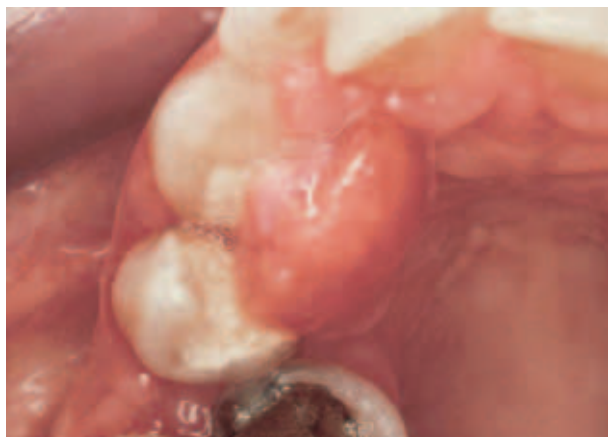This report describes the investigation, diagnosis and management of multiple pyogenic granulomata of the maxillary and mandibular gingivae in a nine-year-old boy. The child presented with a history of spontaneous gingival haemorrhage, gastro-intestinal disturbance and a limp involving his left leg. Investigations revealed a neglected child with the unique oral presentation of multiple pyogenic granulomata and syringomyelia involving the spinal chord between the 5<sup>th</sup> and 8<sup>th</sup> thoracic vertebra, with a consequent motor function deficit that led to the development of a spastic diplegic gait. Joint management with paediatric neurology improved both oral and spinal lesions, but despite arriving at a definitive diagnosis of “disseminated pyogenic granuloma” of the oral cavity, the spinal lesion appeared avascular and was deemed likely to be unrelated. The oral lesions were therefore definitively diagnosed and managed as multiple pyogenic granuloma’s rather than disseminated lesions. This report focuses on multiple and disseminated pyogenic granulomata and syringomyelia as medical conditions, their management and the importance of collaborative care pathways between periodontal and neurological physicians in successful management.

**Key words:** multiple pyogenic granulomata, disseminated pyogenic granulomata, syringomyelia, spontaneous gingival haemorrhage

## INTRODUCTION

Pyogenic granuloma is a relatively common benign lesion of the skin and/or mucosal surfaces, accounting for 0.5% of all skin nodules in children in the United States alone (Lin et al, 2004). The aetiology is still poorly understood but trauma, hormonal influence, viral oncogenes, microscopic arteriovenous malformations and growth factors (e.g. tumour angiogenesis factor – Patrice et al, 1991) have all been implicated in the pathogenic process (Yuan et al, 2004). What is clear is that the term “pyogenic granuloma” is misleading because it implies a granulomatous inflammation or an infected lesion, neither of which are the case. The “granuloma’s” are thought to result from chron-

ic irritation or trauma, which stimulates excessive capillary proliferation (Requena et al, 1997) and the histological term *lobular capillary hemangioma* better describes their true nature. Lesions classically present as red nodules, but may appear exophytic with surface crusting or ulceration. Dermal lesions are most commonly found in younger age groups (mean age of presentation 6.7 years - Pagliai et al, 2004). Most pyogenic granuloma’s are solitary lesions, skin lesions being bright red, shiny papules between a few millimetres in size (average 6.5mm) up to several centimetres. Oral pyogenic granuloma’s classically present during pregnancy as “epulides” arising between the teeth in the inter-dental papilla region (Fig 1). Other forms include:

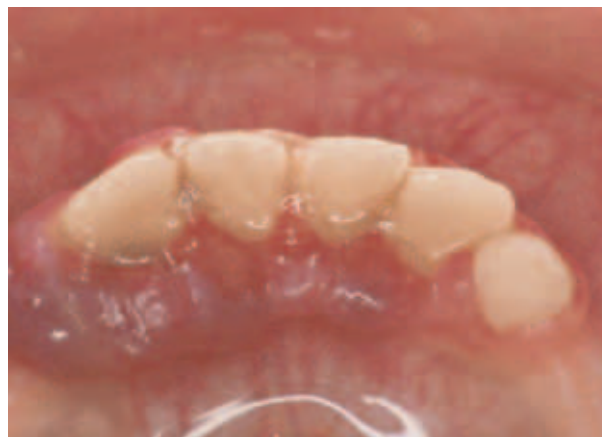

**Fig 1** Pyogenic granuloma arising following irritation by subgingival calculus in a pregnant 27-year-old.

- Disseminated pyogenic granuloma
- Subcutaneous pyogenic granuloma
- Intravenous pyogenic granuloma
- Pyogenic granuloma arising secondary to systemic medication (retinoids and protease inhibitors used in HIV disease) – (Patrice et al, 1991; Ceyhan et al, 1997).

The disseminated form of this pathology is relatively rare, the international literature citing few cases (Momemi et al, 1995) and those reported relate mainly to skin lesions or those involving genital mucosa rather than oral mucosa. Whilst tissue trauma, in particular following burns (Ceyhan et al, 1997), is regarded as the primary cause for localised lesions, this is disputed with disseminated pyogenic granuloma's (Strohal et al, 1991). The literature also confuses the terms "multiple" and "disseminated" and most reports utilise the two terms interchangeably. It is our view that the term "disseminated" implies dispersion of the lesions around several sites in the body, whereas "multiple" refers to several lesions arising at the same anatomical location. Multiple pyogenic granuloma's are extremely rare (Torres et al, 1995) and to the authors knowledge, there are no reports in the literature that describe the intra-oral presentation of this condition.

This paper therefore describes a nine-year-old boy with multiple pyogenic granulomas who was referred to the Paediatric Dental Clinic at Birmingham's Dental Hospital (UK) with a history of spontaneous gingival bleeding and concern expressed by his general dental practitioner about a



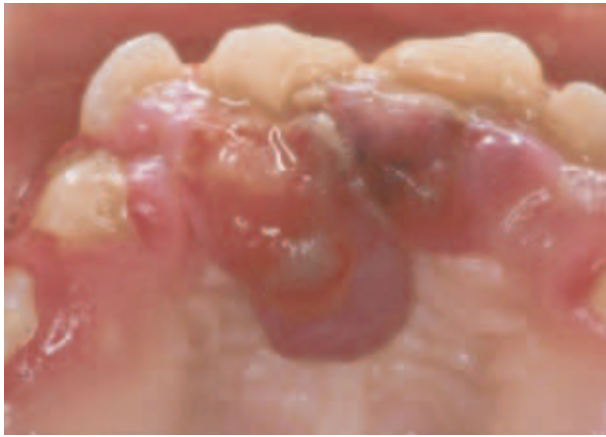
**Fig 2** View of lower labial gingivae with early multiple pyogenic granulomata in the nine-year-old boy reported in this paper.

sinister underlying systemic cause. He was then referred internally to the Periodontal Clinic, where he presented with multiple pathology and an unclear and inaccurate history from his parents, which complicated subsequent investigations. Successful management necessitated a multi-disciplinary approach to investigation, diagnosis and treatment, with frequent communication and discussion between the medical and dental teams to arrive at definitive diagnoses. Ultimately, separate pathology was diagnosed, and joint management of the oral and spinal lesions proved to be successful in the medium term.

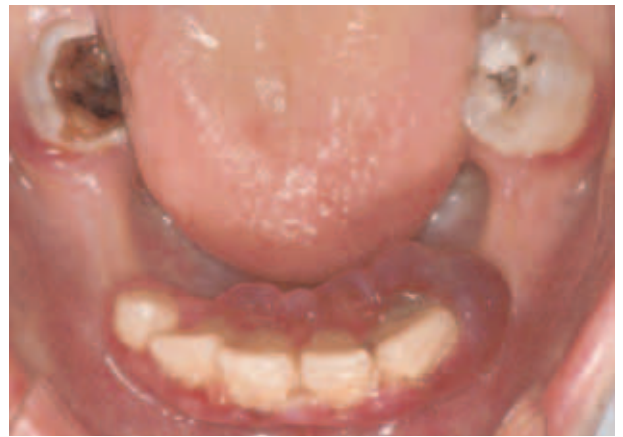## CASE REPORT

A nine-year-old boy was seen for consultation in the Paediatric Department of Birmingham Dental Hospital, following referral by his general dental practitioner to investigate spontaneous gingival bleeding and associated gingival enlargements related to his upper and lower anterior teeth. The history indicated that the overgrowth had started approximately six weeks previously and was progressively deteriorating, causing significant distress to the child and his parents.

The history revealed no apparent initiating factors. Medically, there was a history of chronic constipation, with the child often going for a period of two weeks without passing stools, as well as a history of blood per rectum, but no mucus. His weight had been largely unchanged during this period. There was a family history of leukaemia, Coeliac



**Fig 3** Palatal view of pyogenic lesions affecting the gingivae of the same case as Fig 2.

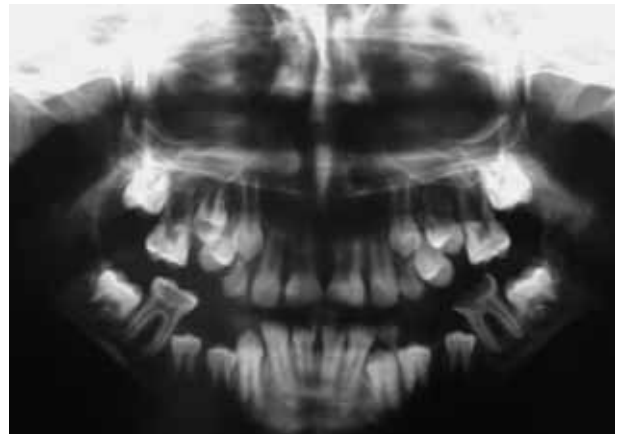


**Fig 4** Carious lower first molar teeth in the presented case, illustrating a neglected mouth.

disease and thrombocytopaenia. In addition to his gastrointestinal symptoms he had a painful left leg, and a spastic gait, which his parents attributed to a playground fall approximately two weeks earlier. Extraorally, he was reasonably well perfused with no pallor of the conjunctiva or nail beds. No lymphadenopathy was detected and the only significant extraoral finding was his unusual gait. Intraorally, there were exophytic vascular overgrowths of the gingivae, with involvement of both free and attached tissues, both in the anterior maxilla and mandible (Fig 2). The vascular overgrowth had a fibrinous margin that was relatively translucent (Fig 3). The remainder of the oral mucosa was normal, although he did have a neglected mouth with several grossly carious teeth (Fig 4). He had clearly been unable to brush his teeth for several weeks, which may have contributed to the apparently pyogenic overgrowths.

An orthopantomogram was requested and this demonstrated a normal chronology to his developing dentition, with no bone loss associated with the oral lesions (Fig 5); the presence of bone loss would have indicated potentially invasive osteolytic lesions, likely to be neoplastic in origin. A differential diagnosis was made of:

1. Bacillary angiomatosis
2. Kaposi's sarcoma
3. Granulomatous inflammation associated with one of the orofacial granulomatoses (e.g. Crohn's disease, sarcoidosis)
4. Histiocytosis-X
5. Unusual form of multiple vascular epulides (pyogenic granulomas)



**Fig 5** Panoramic radiograph demonstrating an absence of underlying bony pathology.

6. Systemic vascular neoplasia (e.g. myeloproliferative disease, acute myeloid leukaemia)
7. Coeliac disease.

Communication was received from a consultant neurologist with regard to the child's deteriorating motor function (leg function) and constipation to ascertain whether there was any link between his oral pathology and his systemic disease. The patient's constipation was being managed by the use of Lactulose and Senokot, but the deterioration in lower limb function had led to a frank spastic diplegic gait, and he had become unable to walk independently and was confined to a wheelchair. A magnetic resonance image (MRI) scan of his spinal chord (Fig 6) demonstrated syringomyelia T5-T8, with the possibility of the syrinx being a

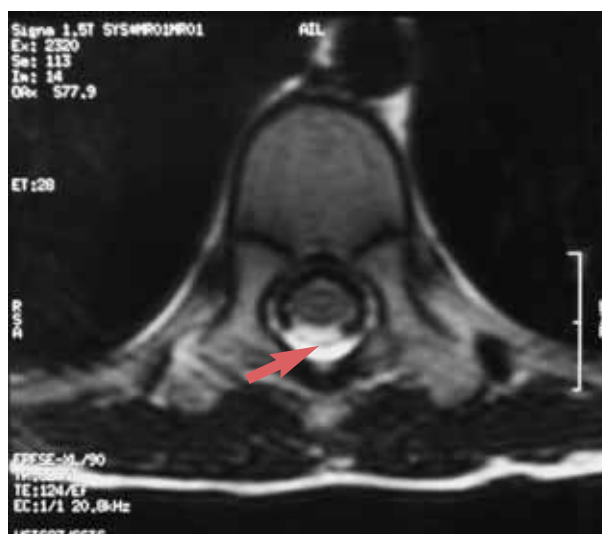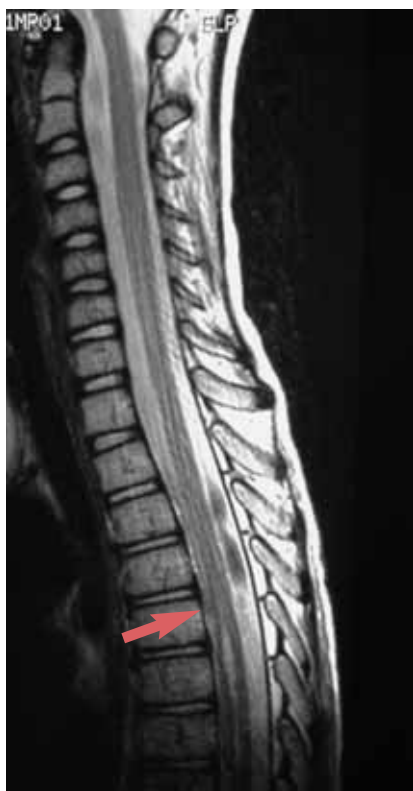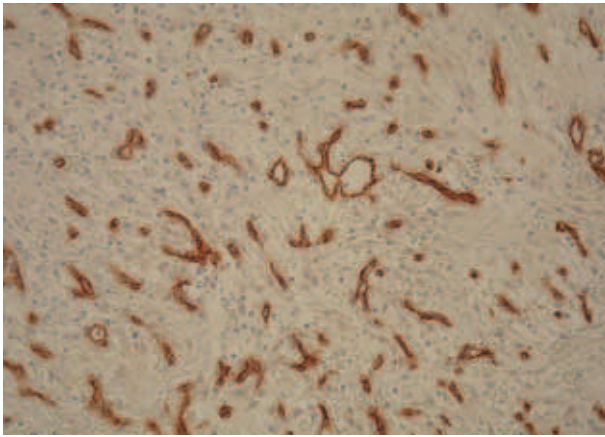


Fig 6a–b MRI scans (both LS and TS sections) of the spinal syrinx (highlighted by arrow).

vascular chord lesion similar to his oral lesions. Within the Periodontal Clinic a full blood count was performed and a differential leukocyte count and blood film requested, to eliminate leukaemia or myeloproliferative disease as potential diagnoses. The results were reported as normal, and his prothrombin time and activated partial thromboplastin time were also reported as being within normal ranges for his age. Routine immunology was requested to investigate non-specific immunoglobulin levels as well as anti-gliadin (inflammatory bowel disease) antibodies and antibodies to tissue transglutaminase (IgA – for Coeliac disease). In addition, C1-esterase inhibitor levels and function were investigated to eliminate angioedema from the differential diagnosis. Serum angiotensin converting enzyme (ACE – for sarcoidosis), liver function tests and a biochemical profile were also performed. The results indicated normal levels of IgA tissue trans-glutaminase antibodies, though total IgA levels were raised at 3.16g/l (normal range 0.7–2.5), as was his complement component C3 at 2.22g/l (normal range 0.75–1.75). The latter were deemed to be due to a robust mucosal immune response, consistent with the inflammatory gingival swellings. A short general anaesthetic appointment was arranged

for excisional biopsy of the disseminated gingival lesions and extraction of the grossly carious teeth. At the time of surgery the oral lesions had almost doubled in size from the initial presentation and were covering the majority of the hard palate. The aggressive behaviour of the lesions raised concerns about malignant vascular neoplasia. Previous experience with a gingival lesion that histologically resembled a pyogenic granuloma, but had subsequently been diagnosed clinically and managed as a Kaposi's sarcoma (KS - Chapple et al, 2000) despite a lack of histological confirmation of the clinical diagnosis, necessitated the adoption of a cautious approach to the investigation of these lesions. Thus, immunostaining for anti-HHV8 antibodies was requested and a negative result effectively ruled out a diagnosis of KS.

Surgery and recovery were uneventful and tissue was sent for routine histopathology and a series of immunological stains (factor VIII related/Von-Willebrands antigen and CD34) to confirm the vascular nature of the lesions. The histopathology essentially demonstrated a vascular pyogenic reaction, which appeared benign and disseminated in nature (Fig 7) The histopathology report stated: "This is consistent with multiple pyogenic granulomas from the gingivectomy site and from the upper right deciduous canine region." A further immunocytochemistry report of the biopsy was negative for HHV8 antibodies, which supported the original diagnosis of multiple pyogenic granulomas.



**Fig 7** Photomicrograph of the excision biopsy from the maxillary lesions, stained immunocytochemically for CD34+ antigens (endothelial cell marker).

One week post-excision, the surgical sites were healing well and the boy's parents were reassured with regard to the benign nature of the biopsy results. An appointment was made with a hygienist for focussed and repeated measures of oral hygiene instruction and fine scaling. After a further three days the patient attended complaining of swelling and bleeding from the lower right first molar extraction socket. Examination revealed a 5cm firm swelling, which was diagnosed clinically as a haematoma. Metronidazole 100 mg TDS for three days was prescribed, and the patient was asked to contact if problems did not resolve. Repeated haematological investigations continued to report normal findings with the exception of a mildly raised plasma fibrinogen, which was deemed consistent with a systemic response to the level of oral infection (Kweider et al, 1993). The patient was reviewed after a further three-month period, where complete healing had taken place. It was noted, however, that the patient's oral hygiene was deteriorating, especially in the mandible, and a further hygienist appointment was made.

After comprehensive clinical investigations and input from medical colleagues a definitive diagnosis was recorded as co-incidental:

1. Multiple pyogenic granuloma's
2. Syringomyelia T5-T8
3. Constipation.

## DISCUSSION

The aetiology of pyogenic granuloma is unknown, but a number of possible causes have been cited in the literature. These include:

- Post traumatic injury to the mucosa.
- Hormonal influences: – these lesions occur more frequently in pregnancy.
- Viral infection: little evidence exists for a viral aetiology, but viral oncogenes have been implicated.
- Underlying microscopic arteriovenous malformations.
- Drug-induced – some association has been found in the literature with systemic retinoids or protease inhibitors.

As far as intraoral aetiology is concerned, extragingival sites frequently have a history of trauma. Gingival lesions however are often associated with irritation of the gingival tissues by plaque accumulation or other local factors such as inadequate restorations or calculus deposits. Hormonal changes in pregnancy are also associated with intra oral pyogenic granuloma formation.

Pyogenic granuloma is a common lesion and presents most frequently as a solitary lesion in children and young adults. It presents as a red papule or nodule that is prone to inflammation and bleeding. It rarely presents as a multiple lesion (at the same anatomical site, e.g. oral cavity) or disseminated lesion (involving different anatomical sites).

Removal of such lesions is indicated when diagnostic uncertainty exists, function is compromised, the lesion bleeds or there are aesthetic concerns. Removal can be achieved in a number of ways, including:

- Surgical excision
- Shave curettage and cauterisation – the lesion is shaved off and the resultant bleeding stemmed by cauterisation
- Pulse dye laser surgery
- Cryosurgery
- Chemical cauterisation, using silver nitrate.

Gingival lesions require surgical removal down to the periosteum, along with removal of any local irritant features (e.g. overhanging restorations, calculus) Pyogenic granuloma occasionally recurs and in such cases removal will need to be re-



peated. Lesions removed during pregnancy have a higher incidence of reoccurrence. Therefore in such patients removal is best left until the postpartum period.

Syringomyelia as reported from the MRI scan is a disorder of the spinal cord in which cysts form. The cyst is termed a "syrinx" and can expand over time resulting in damage to the spinal cord. This damage can present as pain or weakness in the muscles supplied by the nerves that are damaged in the cord, which includes back, shoulders, arms and legs. The presentation can be quite variable, with patients experiencing a combination of symptoms. Two forms of syringomyelia have been identified: the first is associated with a malformation of the brain causing malpositioning of the cerebellum, where a syrinx may develop. Symptoms in this case are often seen in the 25–40-year age groups. The second major form arises post-trauma or as a complication of meningitis, haemorrhage or tumour. In this case the cyst develops in a particular part of the spinal cord that has been damaged. The symptoms may start months or years after the initial insult.

Diagnosis (as in this case) requires the use of MRI scanning, and whilst other investigations may be used to help confirm the diagnosis, the advent of MRI has largely superseded these investigations. One of the confirmatory tests measures muscle weakness (electromyography), others use cerebrospinal fluid pressure levels which can indicate the presence of expanding lesions in the spinal cord. Treatment of syringomyelia is dependent on the position of the lesion, and surgical removal or drainage can stabilise the symptoms or produce a modest improvement. In the absence of symptoms it is not usually treated.

This rare and complex case highlights a number of important issues, not only in relation to this case but in the general management of patients who present with systemic diseases affecting the periodontal tissues:

- It is not always wise to obtain a history from a child's parents in preference to the minor themselves, because whilst there may be a perceived greater accuracy and clarity with a parental history, this proved misleading in the current case. The parents were keen to help but somewhat dominant, not allowing the child to recall their chronological history of events, with the result that the limp appeared to arise

following a fall, whereas in truth the limp had arisen secondary to the syringomyelia and led to the child falling.

- Prompt referral of patients who present with unusual lesions is essential. As much information as possible should be included, both in terms of describing the lesion and any relevant systemic factors. This allows the referral centre to assess the urgency of the case and arrange for a prompt appointment if this is deemed necessary. In the case presented, the size of the surgical excision was reduced by the early referral.
- The focus of examination should not be on the most obvious clinical pathology, and the patient should be questioned and investigated as a whole in order that any systemic factors or lesions, which may or may not be related to the primary pathology, are identified and fully investigated. Multiple pathology may be evident and missed if the focus of the investigation is limited to the reason for referral.
- The differential diagnosis is essential because it guides further investigations in a focussed manner, rather than performing a routine screen of various haematological, immunological or biochemical markers, which are expensive and often unhelpful in determining the definitive diagnosis.
- The multidisciplinary approach is important to diagnosis and management of periodontal manifestations of systemic diseases, pooling of expertise can only be of benefit to both patient and clinician.

## SUMMARY

This paper describes a rare oral presentation of multiple pyogenic granuloma's and illustrates how joint management helped rule out disseminated disease and led to the identification of dual pathology, requiring distinct management strategies.

It highlights the importance of liaising with medical colleagues to help with diagnostic and management strategies. Finally, it is to our knowledge the first reported case of multiple pyogenic granulomata affecting the oral mucosa.

## ACKNOWLEDGEMENTS

We are grateful to Dr H Williams for the pathology report and photomicrograph (Fig 7).

## REFERENCES

- Ceyhan M, Erdem G, Kotiloglu E, et al. Pyogenic granuloma with multiple dissemination in a burn lesion. *Pediatr Dermatol* 1997;14:213–215.
- Chapple ILC, Hamburger J. The significance of oral health in HIV disease. *J Sex Trans Inf.* 2000;76:236–243.
- Kweider M, Lowe GDO, Murray GD, Kinane DF, McGowan DA. Dental disease, fibrinogen and white cell count; links with myocardial infarction? *Scott Med J* 1993;38:73–74.
- Lin RL, Janniger CK. Pyogenic granuloma. *Cutis* 2004;74:4,229–233.
- Momeni AZ, Enshaieh S, Sodifi M, Aminjawaheri. Multiple giant disseminated pyogenic granuloma in three patients burned by boiling milk. *Int J Dermatol* 1995;34:707–710.
- Pagliai KA, Cohen BA. Pyogenic granuloma in children. *Pediatric Dermatology* 2004;21:1,10.
- Patrice SJ, Wiss K, Mulliken JB. Pyogenic granuloma (lobular capillary hemangioma): a clinicopathologic study of 178 cases. *Pediatr Dermatol* 1991;8:267–276.
- Requena L, Sanguenza OP. Cutaneous vascular proliferations. Part II. Hyperplasias and benign neoplasms. *J Am Acad Dermatol* 1997;37:887–919.
- Strohal R, Gillitzer R, Zonzits E, Stingl G. Localized vs generalized pyogenic granuloma. A clinicopathologic study. *Arch Dermatol* 1991; 27:856–861.
- Torres JE, Sanchez JL. Disseminated pyogenic granuloma developing after exfoliative dermatitis. *J Am Acad Dermatol* 1995;32:280–282.
- Yuan K, Lin MT. The roles of vascular endothelial growth factor and angiopoietin-2 in the regression of pregnancy pyogenic granuloma. *Oral Diseases.* 2004;10:3, 179–185.

**Reprint requests**

Iain LC Chapple  
 Birmingham Dental School  
 St Chads Queensway  
 Birmingham  
 B4 6NN  
 E-mail: I.L.C. Chapple@bham.ac.uk