

Local Periodontal Therapy with Subgingival Controlled Release of Chlorhexidine – A Case Report

Lutz Harnack, José Gonzales, Jörg Meyle

A 47-year-old patient presented at the Department of Periodontology of our Dental School with severe chronic periodontitis. Periodontal examination revealed probing pocket depths (PPD) and clinical attachment loss (CAL) of more than 10 mm in several teeth. A total of 28 teeth were present, with 26 teeth showing PPD > 5 mm with bleeding on probing (BOP). Molars presented with furcation lesions class I and II. Additionally, poorly contoured restorations were present. Oral hygiene instructions and motivation were performed in order to reduce the plaque and papillary bleeding indexes. Subsequently, and prior to scaling and root planing (SRP), a subgingival controlled release of chlorhexidine (PerioChip®) was performed on all teeth with PPD > 5 mm for a total of 10 days. Afterwards, a full mouth SRP was conducted by a experienced dental hygienist. Periodontal parameters were assessed again after four weeks and three months.

Key words: PerioChip®, chlorhexidine, severe chronic periodontitis, local therapy

INTRODUCTION

The success of periodontal treatment is not only based on the improvement of the clinical parameters. It also depends on the changes in the microbiological composition of the subgingival flora, as substantial reduction or a complete elimination of the exogenous pathogens in the subgingival flora should be reached (Bollen and Quirynen, 1996). Chemical agents have already been used for centuries to obtain or maintain oral health. For therapeutic reasons, pharmaceuticals must be delivered at an effective concentration and for an adequate length of time. Gingival crevicular fluid flow averages 20 µl/h and increases with gingival inflammation (Cimasoni, 1983), which is equivalent to a turnover of 40 times/hour in a medium-sized periodontal pocket with a volume of 0.5 µl.

Subgingival antimicrobials can be effectively administered by non-controlled delivery devices (e.g.

povidone-iodine). They are able to kill microorganisms rapidly enough to overcome the drug-diluting effect of the gingival crevicular fluid. The controlled drug delivery devices, however, allow relatively slow-acting antimicrobial agents to maintain sufficiently high microbicidal concentrations long enough to be effective. In the 1970s, Goodson et al (1979) first proposed the concept of 'controlled local delivery of antibiotics' in the treatment of periodontitis (Goodson et al, 1979). Since the introduction of tetracycline fibers to dentistry, several other products, all biodegradable, have been developed and studied. These include doxycycline polymer (Jorgensen et al, 2004), metronidazole gel (Perinetti et al, 2004) and the chlorhexidine chip (Soskolne et al, 2003). Chlorhexidine (CHX) is a cationic bisguanide agent that can attach to the negatively charged bacterial cell membrane and thus cause a leak and is in consequence bactericidal. It also prevents bacteria at

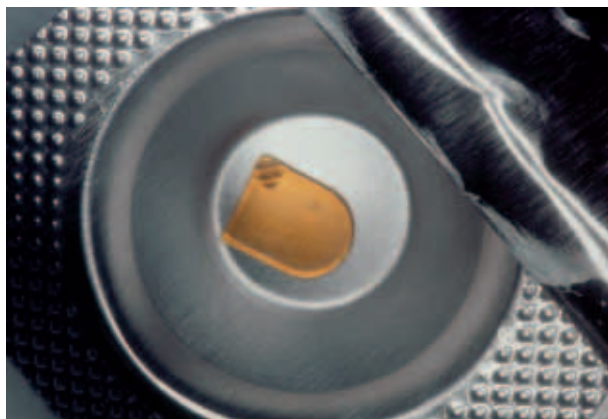

Fig 1 PerioChip® in its package.

taching to each other, or to a surface (Hennessey, 1973). CHX is the most effective antimicrobial mouthrinse. It has a high substantivity (Bonesvoll and Gjermo, 1978), there are detectable amounts of CHX in saliva 24 hours after its application. Several side effects, such as extrinsic staining, taste disturbance, and mucosal erosion, have been reported (Flotra et al, 1971).

The chlorhexidine chip (PerioChip®, Dexcel Pharma GmbH, Alzenau, Germany) is an orange-brown rectangular chip rounded on one end (Fig 1). It measures 4 mm by 5 mm by 0.35 mm, weighs 7.4 mg and contains 2.5 mg of chlorhexidine gluconate on a gelatine matrix. The chip is biodegradable and indicated for use in periodontal pockets that are 5 mm or deeper.

In an *in vitro* study, Stanley et al (1989) reported that CHX concentration of 125 µg/ml inhibited the growth of 99% of the pocket microflora (Stanley et al, 1989). In a pharmacokinetic study, Soskolne et al (1998) reported a peak average CHX concentration in the crevicular fluid of 2007 µg/ml after two hours (Soskolne et al, 1998). For the next 96 hours, the average CHX concentrations were 1300–1900 µg/ml. This was followed by a gradual decline of the CHX concentrations to the end of the study with the average concentration greater than 125 µg/ml for eight days. At the end of the study there was no chip residue in any of the periodontal pockets. Additionally, it has been shown that the CHX chip was most effective when it was placed every three months in pockets that remained ≥ 5 mm in depth (Killooy, 1998). Soskolne et al (1997) indicated

that the PerioChip® can maintain clinically effective levels of CHX in the gingival crevicular fluid (GCF) of periodontal pockets for over one week with no detectable systemic absorption (Soskolne et al, 1997). Recent studies have demonstrated significant clinical improvements by using the PerioChip® as sustained local delivery device (Table 1).

The aim of this case report is to present the procedure of using PerioChip® as sustained local delivery device during the antiinfectious therapy and prior to scaling and root planing in a 47-year-old man with severe chronic periodontitis.

MEDICAL HISTORY

The patient was in good health and was a non-smoker. He was referred for treatment to the Department of Periodontology, University of Giessen, because he expressed having spontaneous bleeding.

Extra- and Intraoral Examinations

Routine inspection of the extraoral structures and intraoral tissues showed no abnormalities.

Periodontal Screening Index and Diagnosis

The Periodontal Screening Index (PSI) was recorded first (Meyle and Vonholdt, 2002). According to the American Academy of Periodontology (AAP), common risk factors should be evaluated in order to detect potential associations between periodontal status and general health conditions. In this case, a PSI of 4 was recorded and no risk factors were identified.

Dental examination showed that in the upper jaw, teeth 18 and 26 were missing. In the lower jaw, teeth 41 and 46 were missing. None of the teeth had been treated endodontically and responded positively to the pulp vitality test with compressed CO₂. Teeth 17, 16, 15, 37, 36 and 35 had poorly contoured amalgam fillings. Teeth 25–27, 31–42 and 45–47 supported poorly contoured metal ceramic crowns.

The examination showed generalized probing pocket depths of more than 10 mm with bleeding on probing. Localized findings like gingival recessions were marked with an asterisk. Furthermore,

Table 1 Subgingival controlled release of chlorhexidine in periodontal treatment.

Type of therapy	Results	Author
Periodontal maintenance therapy over two years	Continuous decrease in PD of 0.95 mm at sites with PD \geq 5 mm	(Soskolne et al, 2003)
As adjunctive prior to periodontal regeneration	Significantly more bone height (3.54 \pm 0.45 mm) with CHX chip as without (1.49 \pm 0.22 mm) CHX chip	(Reddy et al, 2003)
CHX chip application following SRP	Higher reduction of PD and improvement in CAL in the SRP+CHX group compared to SRP alone at three and six months	(Azmak et al, 2002)
As adjunctive prior to periodontal surgery	In general practice, routine use of the CHX chip suggests that costs will be partially offset by reduced surgery over at least one year	(Henke et al, 2001)
CHX chip used as an adjunct to scaling and root planing in maintaining alveolar bone over a nine-month period	The CHX chip significantly reduces loss of alveolar bone in comparison to SRP alone	(Jeffcoat et al, 2000)
CHX chip used as an adjunct to scaling and root planing	Greater mean reductions in PD when the CHX chip was used in conjunction with SRP than when SRP was used alone (1.16 mm vs. 0.7 mm)	(Killooy, 1999)
CHX chip used as an adjunct to scaling and root planing	Greater PD reduction of 2 mm or more at nine month in the CHX chip group (19%) compared with SRP controls (8%)	(Jeffcoat et al, 1998)

PD = pocket depth,
CAL= clinical attachment level,
CHX = chlorhexidine,
SRP = scaling and root planing

an overall plaque index was recorded as presence or absence of plaque at four sites/tooth using the modified O'Leary plaque index (O'Leary et al, 1972). An overall plaque index of 63% was recorded.

Based on the age of the patient, the severe depth of the periodontal pockets, and the insufficient oral hygiene, the diagnosis of severe chronic periodontitis (CP) was established.

Radiographic Examination

The panoramic radiograph revealed the following features (Fig 2): a severe, generalized horizontal alveolar bone loss was apparent in the upper and lower jaw. The bone height was horizontally reduced up to the middle of the root length. Angular radiographic bone loss was detected at the following teeth: 17, 16, 15, 24, 37, 36 and 47.

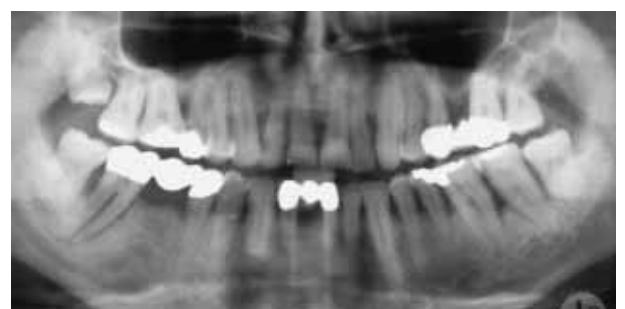
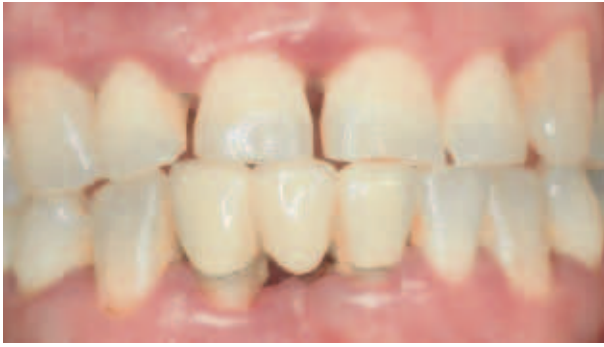
Fig 2 Initial orthopantograph.

No apical lesions were present.

Initial Periodontal Examination

At this stage, initial clinical photographs were taken (Figs 3a-e). Then, the following clinical param-



Figs 3a to e Intraoral appearance prior to the anti-infective therapy.

Fig 3a Frontal view.

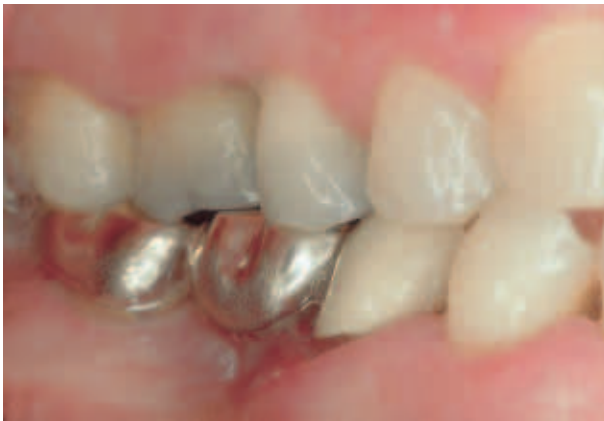

Fig 3b Lateral right view.

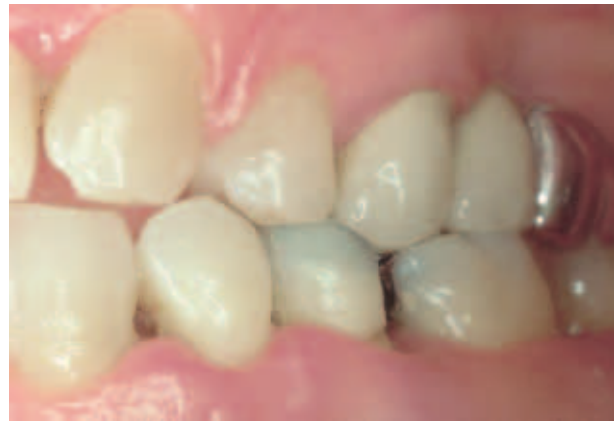

Fig 3c Lateral left view.

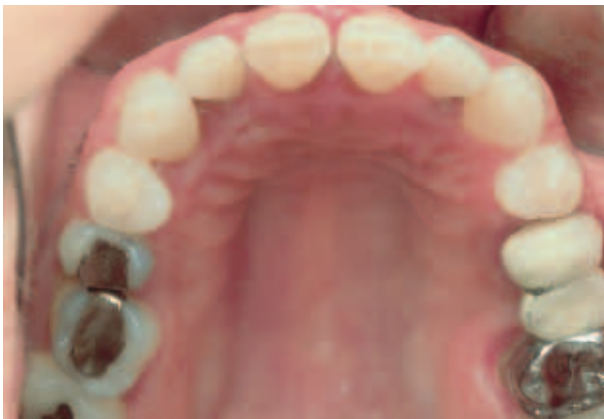

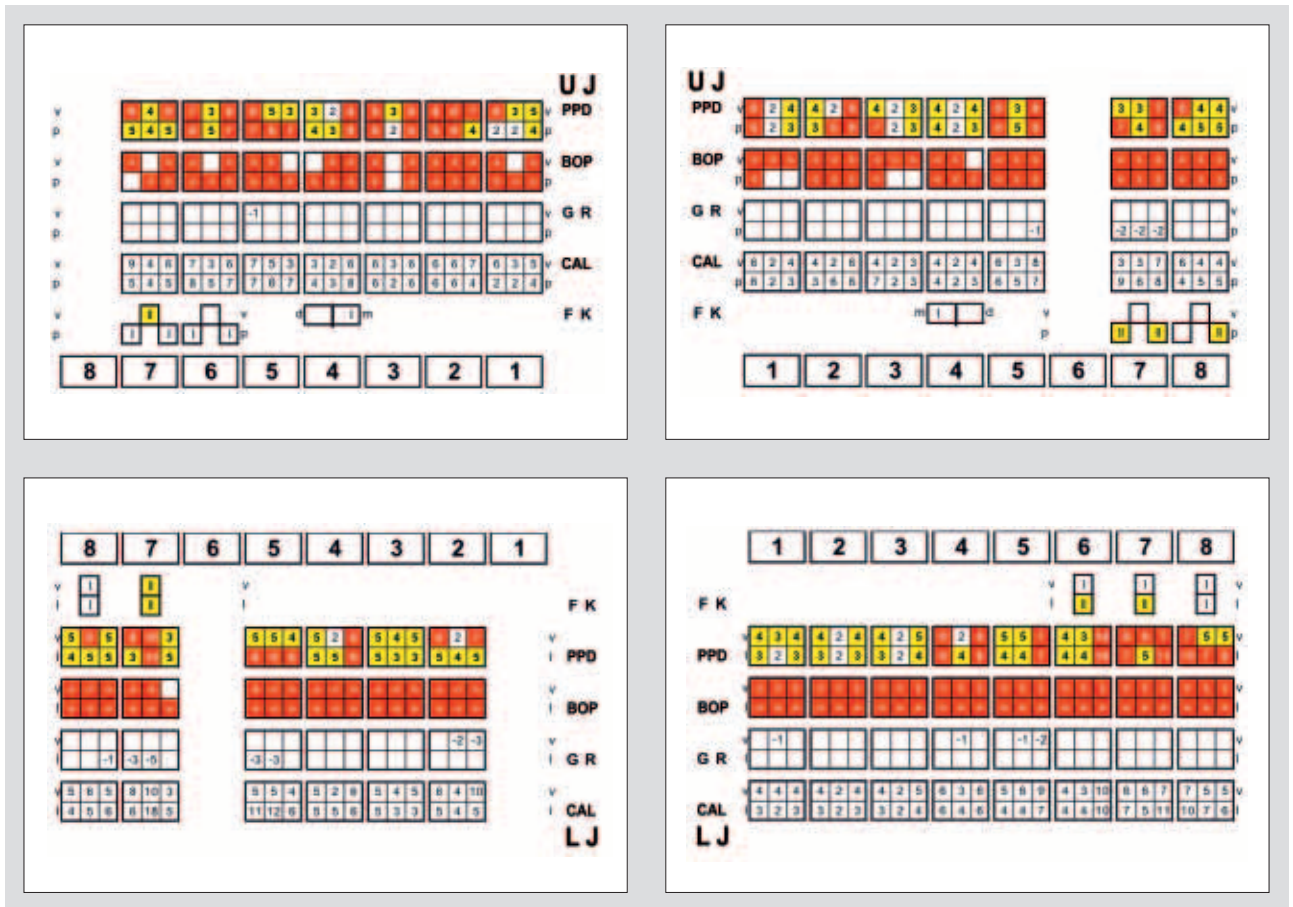
Fig 3d Occlusal view of the maxilla.

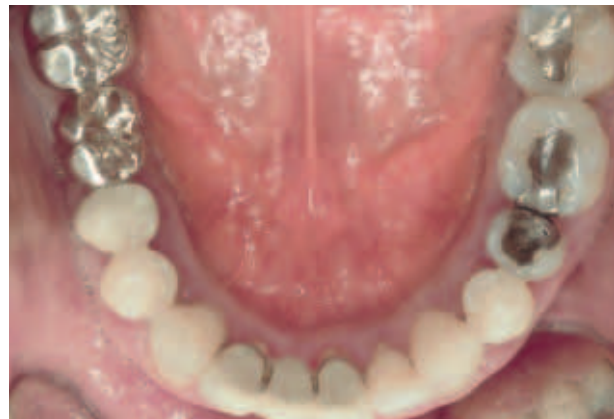

Fig 3e Occlusal view of the mandible.

eters were recorded using the PCP-UNC-15 periodontal probe (Hu-Friedy Mfg. Co Inc, Leimen, Germany): probing pocket depth (PPD), bleeding on probing (BOP), clinical attachment level (CAL), and the level of the gingival recession (GR) at six sites/tooth. Furcation involvements (FK) were also examined (Figs 4a-d). The clinical parameters

showed that of a total of 28 teeth present – 23 teeth were detected with PPD > 5 mm (82%), with bleeding on probing (BOP = 92%). PPD of up to 13 mm was measured. All molars in the upper and lower jaws showed furcation lesions class I and class II. Tooth mobility grade I was measured in several teeth.



Figs 4a to d Initial periodontal examination.

SUPRAGINGIVAL ANTI-INFECTIVE THERAPY

Following the periodontal examination, the patient received oral hygiene instructions and motivation. Supragingival debridement and contouring of the fillings and crowns were performed. During this phase, a modified plaque index (PLI) and papillary bleeding index (PBI) were assessed at four sites/tooth. Patient compliance was good, thus PLI and PBI improved considerably (Fig 5).

Subgingival Anti-infective Therapy with PerioChip®

After the supragingival anti-infective therapy, the PerioChip® was placed in every pocket presenting with PPD > 5 mm with bleeding on probing (BOP) ($n = 23$) (Fig 6). If the tooth showed two or

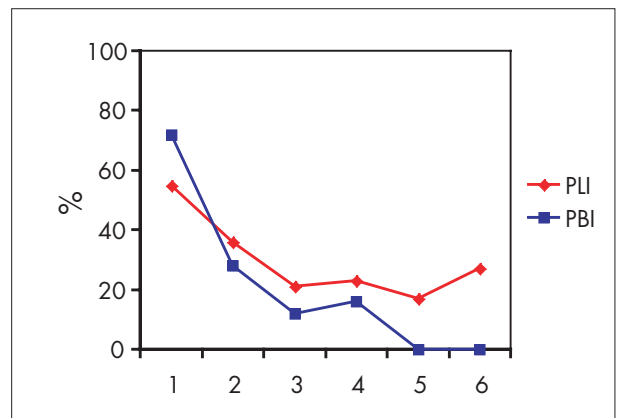


Fig 5 Oral hygiene indices during the anti-infective therapy. PLI = modified plaque index, PBI = modified papillary bleeding index.

more pockets with PPD > 5 mm, a maximum of two chips were introduced.

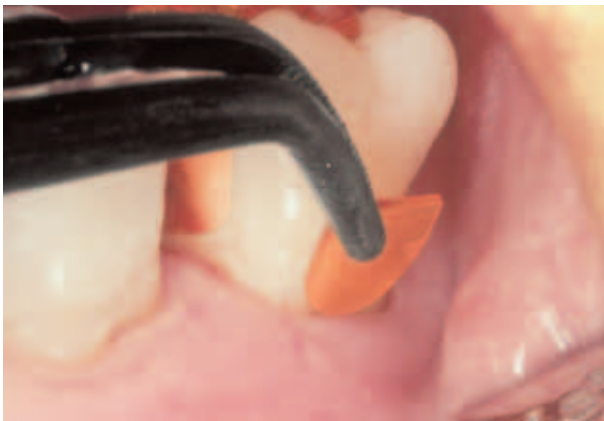

Fig 6 Insertion of a PerioChip® in a pocket ≥ 5 mm.

The chips stayed in place for a total of 10 days. During this period, the patient continued with normal tooth brushing. The use of dental floss around teeth with chips inserted was not allowed in order to avoid displacements of the chips. After ten days it was obvious that every chip was completely re-sorbed.

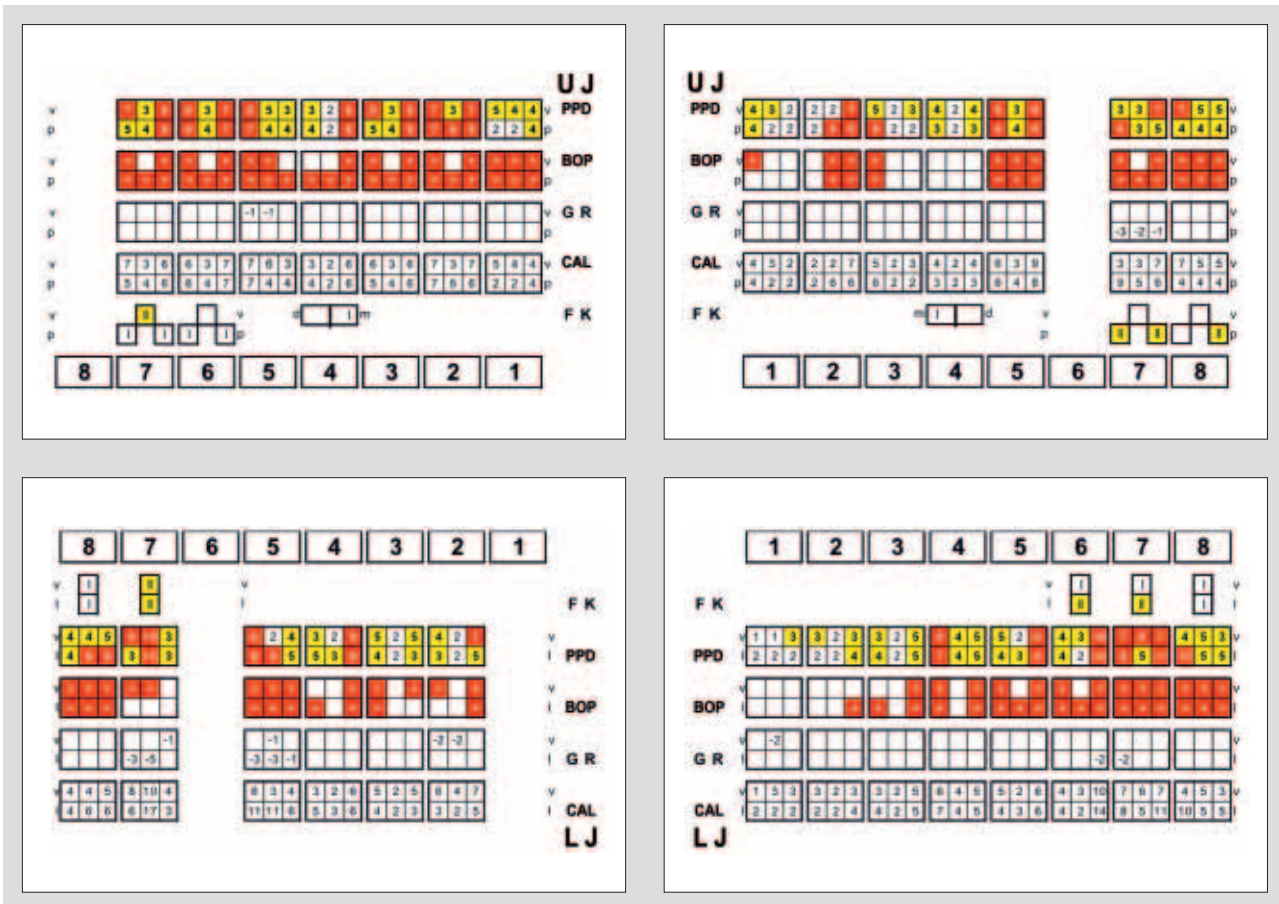
Periodontal Examination after Subgingival Anti-infective Therapy with PerioChip®

After 10 days, again, the clinical parameters PPD, CAL, BOP, and GR were recorded at six sites/tooth. Furcation involvements were examined (Figs 7a-d).

After 10 days, the clinical parameters changed, however, only slight improvements in PPD and BOP were observed. At this time, a total of 21 teeth (75%) presented with PPD > 5 mm. The percent of bleeding on probing (BOP) was reduced from 92% to 66%.

The clinical symptoms of local inflammation were reduced in comparison with the first examination (Figs 8a-e).

The gingival tissues presented with less redness and inflammation. Due to the supragingival debridement and the oral hygiene instructions there was a considerable reduction on hard and soft tooth deposits.



Figs 7a to d Periodontal examination after treatment with PerioChip®.

Figs 8a to e Intraoral appearance after treatment with PerioChip®.

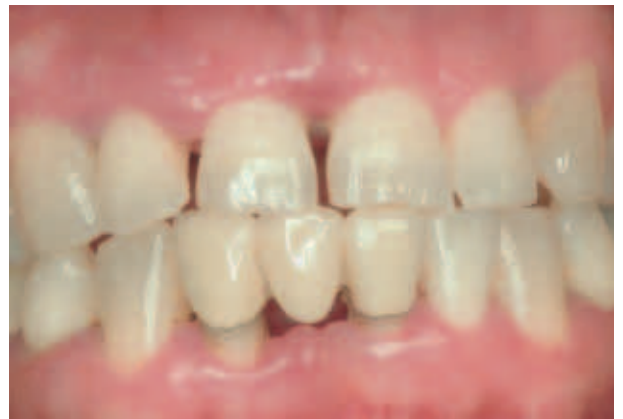

Fig 8a Frontal view.

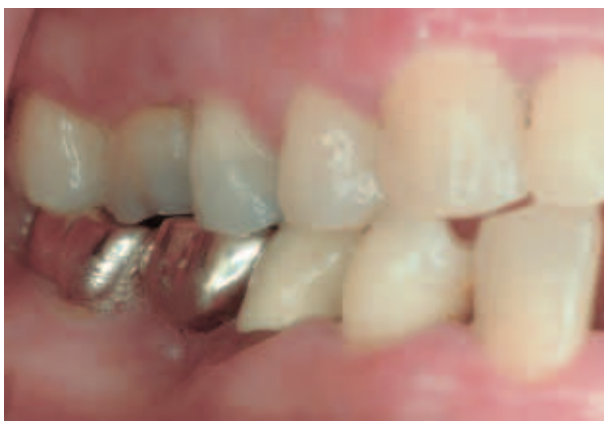

Fig 8b Lateral right view.

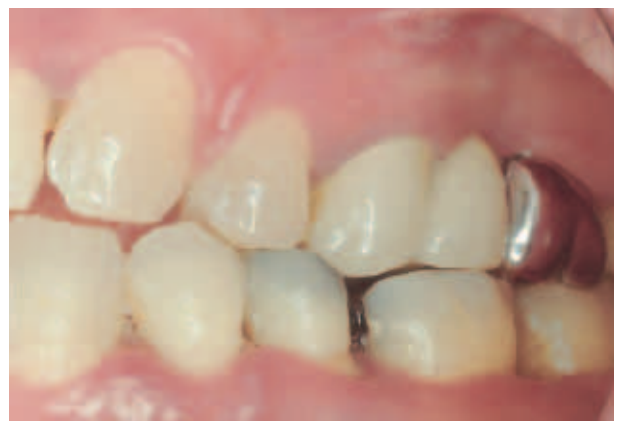

Fig 8c Lateral left view.

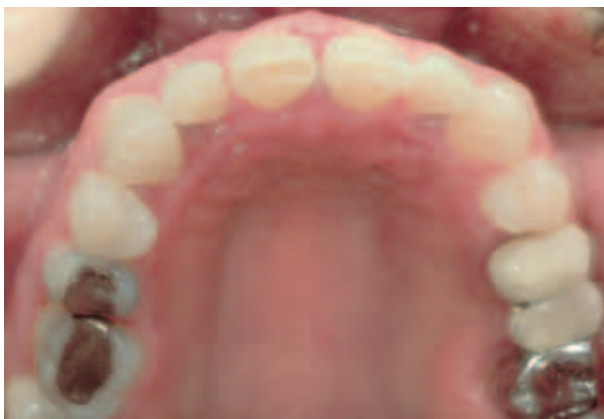

Fig 8d Occlusal view of the maxilla.

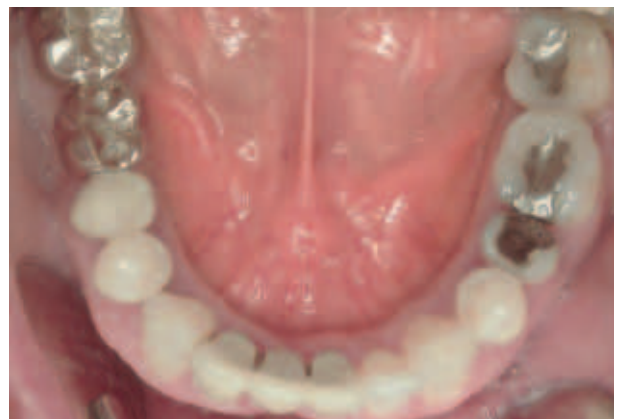

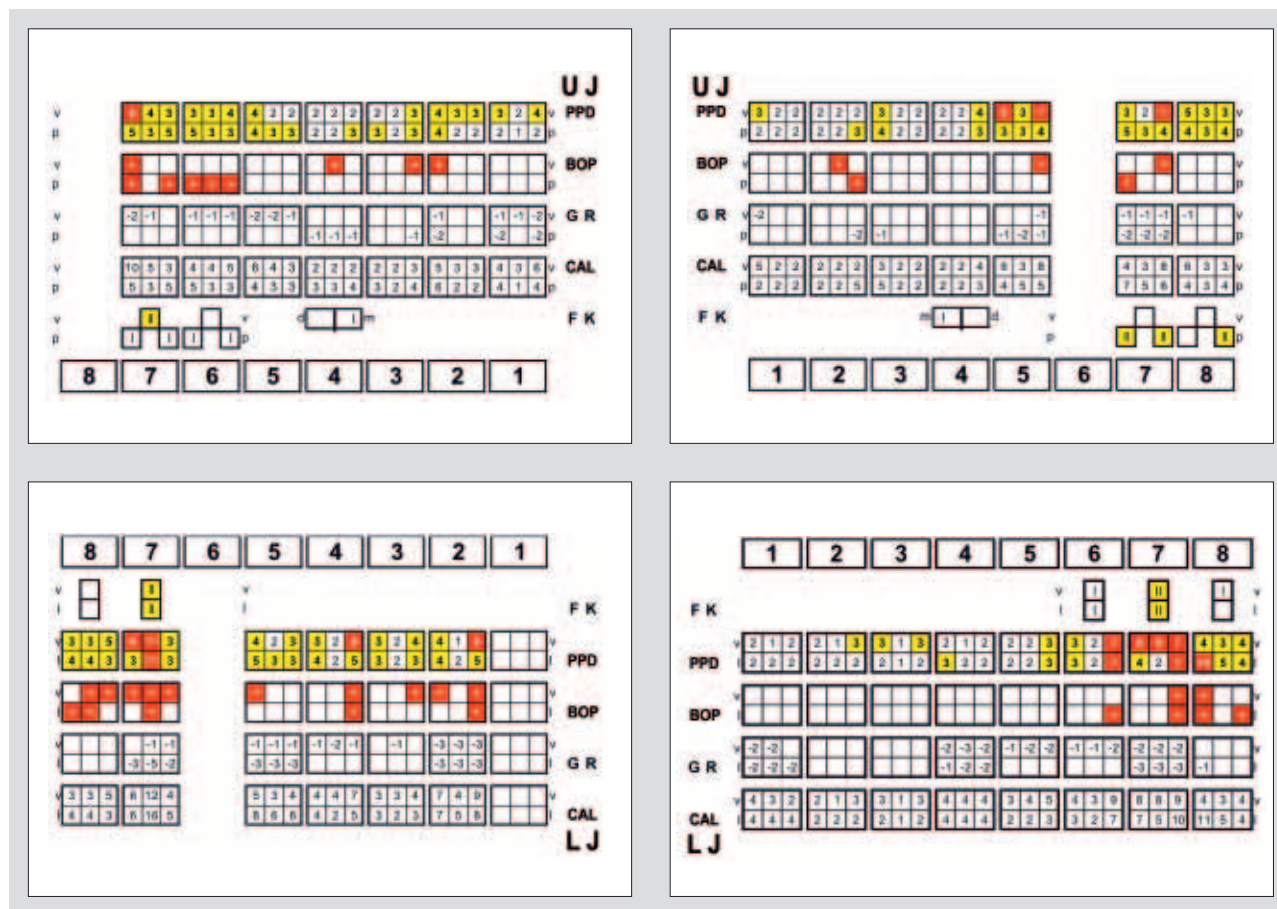
Fig 8e Occlusal view of the mandible.

Further Treatment

At the same time of the second examination a full mouth SRP was performed by a experienced dental hygienist. After completion of the treatment, new PerioChips® were placed in the same periodontal pockets as before SRP.

Periodontal Examination Three Months after Subgingival Anti-infective Therapy with PerioChip® and SRP

After three months, the clinical parameters PPD, CAL, BOP, FK and GR were again recorded (Figs 9a-d). None of the teeth were extracted until this



Figs 9a to d Periodontal examination three months after treatment with PeriChip®.

time. The clinical parameters improved considerably. At three months, nine teeth (32%) presented with PPD > 5 mm, and BOP was present in 20% of the total teeth.

The effectiveness of the anti-infective therapy can be detected in the intraoral appearance after three months. The tissues showed considerably less inflammation (Figs 10a–d). Resulting soft-tissue contours were better and the gums did not show any bleeding. However, further treatment is needed.

EPICRISIS AND PROGNOSIS

The patient was in good general health with no known allergies, took no medication and did not smoke. Clinical examination revealed several teeth (82%) with probing pocket depth > 5 mm and bleeding on probing (92%). Some teeth showed PPD of 10 mm and more. Also, poorly contoured and exposed metal-ceramic restorations

and gingival recessions of different dimensions were present. After periodontal examination, the diagnosis of 'severe chronic periodontitis' (CP) was established based on the age of the patient, the generalized deep periodontal pockets and the moderate oral hygiene.

For the anti-infective therapy, first, repeatedly professional supragingival debridement and motivation were done. Patient compliance improved considerably – the PLI dropped from 70% to 17%. Subsequently, and prior to subgingival scaling and root planing (SRP), PeriChip® placement was performed in all teeth presenting with PPD > 5 mm and BOP. The chips were placed for a total of 10 days. Immediately after, new clinical parameters were assessed. Then, a full mouth SRP was performed by an experienced dental hygienist. After that, and with exception of home care oral hygiene, no other treatment was undertaken during a period of three months, when the clinical parameters were assessed again.

Figs 10a to e Intraoral appearance three months after treatment with PerioChip®.

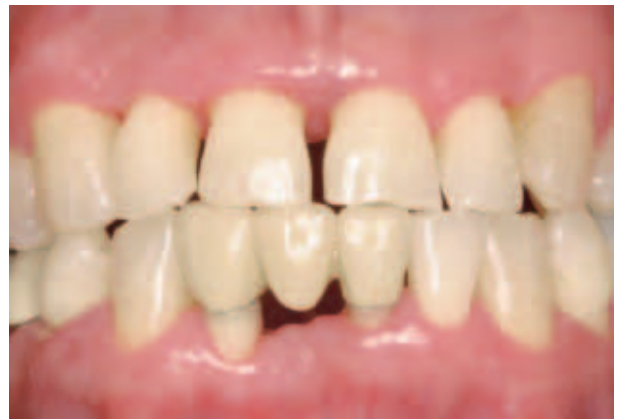

Fig 10a Frontal view.

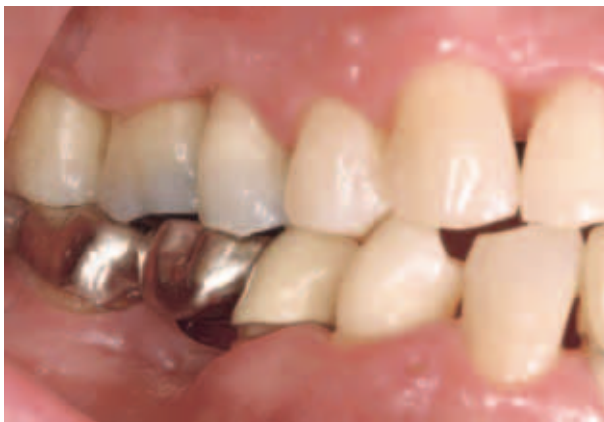

Fig 10b Lateral right view.

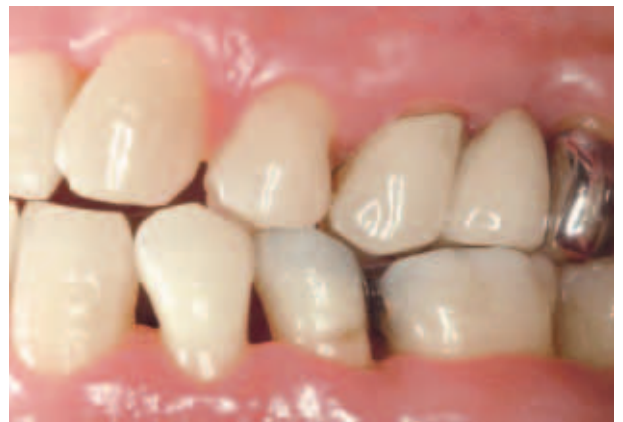

Fig 10c Lateral left view.

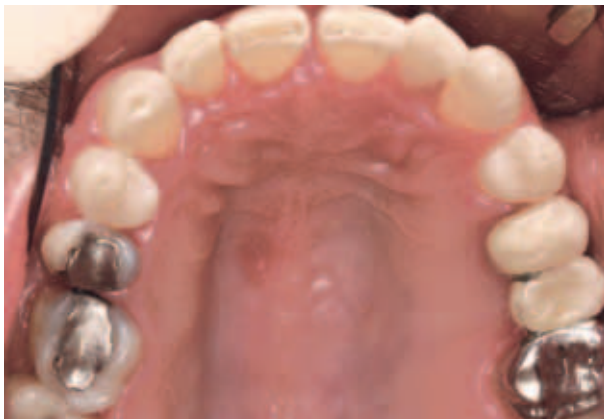

Fig 10d Occlusal view of the maxilla.

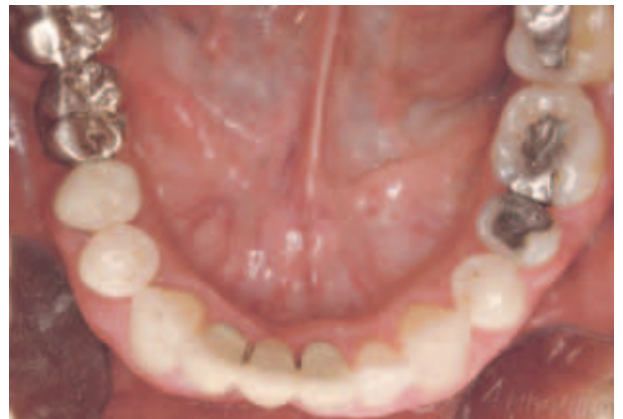

Fig 10e Occlusal view of the mandible.

The periodontal clinical parameters slightly improved after 10 days of chip placement. The amount of PPD > 5 mm was reduced from 82% at baseline to 75% after 10 days, and the amount of BOP was reduced from 92% to 66%. This indicates the effectiveness of subgingival an-

ti-infective therapy with PerioChip® in reducing bleeding on probing after 10 days. After three months the clinical parameters improved considerably. The amount of PPD > 5 mm was reduced from 82% at baseline to 32%. The amount of BOP was reduced from 92% to 20%.

These results reflect the effect of the subgingival anti-infective therapy with SRP.

The follow-up treatment of the patient comprises periodontal surgeries and the restorative treatment. Patient compliance and participation in the further supportive periodontal treatment will maintain the results and provide an overall good prognosis.

This case report indicates that local placement of PerioChip® prior to SRP is effective in reducing local inflammation. The patient did not report on any discomfort due to the chip placement. Further clinical controlled studies are needed to confirm this observation.

REFERENCES

- Azmak N, Atilla G, Luoto H, Sorsa T: The effect of subgingival controlled-release delivery of chlorhexidine chip on clinical parameters and matrix metalloproteinase-8 levels in gingival crevicular fluid. *J Periodontol* 2002;73:608–615.
- Bollen CM, Quirynen M: Microbiological response to mechanical treatment in combination with adjunctive therapy. A review of the literature. *J Periodontol* 1996; 67: 1143–1158.
- Bonesvoll P, Gjermo P: A comparison between chlorhexidine and some quaternary ammonium compounds with regard to retention, salivary concentration and plaque-inhibiting effect in the human mouth after mouth rinses. *Arch Oral Biol* 1978;23:289–294.
- Cimasoni G: Crevicular fluid updated. *Monogr Oral Sci* 1983;12:III–VII,1–152.
- Flotra L, Gjermo P, Rolla G, Waerhaug J: Side effects of chlorhexidine mouth washes. *Scand J Dent Res* 1971; 79:119–125.
- Goodson JM, Haffajee A, Socransky SS: Periodontal therapy by local delivery of tetracycline. *J Clin Periodontol* 1979; 6:83–92.
- Henke CJ, Villa KF, Aichelmann-Reidy ME, Armitage GC, Eber RM, Genco RJ, Killoy WJ, Miller DP, Page RC, Polson AM, Ryder MI, Silva SJ, Somerman MJ, Van Dyke TE, Wolff LF, Evans CJ, Finkelman RD: An economic evaluation of a chlorhexidine chip for treating chronic periodontitis: the CHIP (chlorhexidine in periodontitis) study. *JADA* 2001;132:1557–1569.
- Hennessey TS: Some antibacterial properties of chlorhexidine. *J Periodontal Res Suppl* 1973;12:61–67.
- Jeffcoat MK, Bray KS, Ciancio SG, Dentino AR, Fine DH, Gordon JM, Gunsolley JC, Killoy WJ, Lowenguth RA, Magnusson NI, Offenbacher S, Palcanis KG, Proskin HM, Finkelman RD, Flashner M: Adjunctive use of a subgingival controlled-release chlorhexidine chip reduces probing depth and improves attachment level compared with scaling and root planing alone. *J Periodontol* 1998; 69:989–997.
- Jeffcoat MK, Palcanis KG, Weatherford TW, Reese M, Geurs NC, Flashner M: Use of a biodegradable chlorhexidine chip in the treatment of adult periodontitis: clinical and radiographic findings. *J Periodontol* 2000; 71:256–262.
- Jorgensen MG, Safarian A, Daneshmand N, Keim RJ, Slots J: Initial antimicrobial effect of controlled-release doxycycline in subgingival sites. *J Periodontal Res* 2004;39:315–319.
- Killoy WJ: The use of locally delivered chlorhexidine in the treatment of periodontitis. Clinical results. *J Clin Periodontol* 1998;25:953–958.
- Killoy WJ: Assessing the effectiveness of locally delivered chlorhexidine in the treatment of periodontitis. *JADA* 1999;130:567–570.
- Meyle J, Vonholdt J: Parodontale Screeninguntersuchung. *Parodontologie* 2002;13:119–129.
- O'Leary TJ, Drake RB, Naylor JE: The plaque control record. *J Periodontol* 1972;43:38–42.
- Perinetti G, Paolantonio M, Cordella C, D'Ercole S, Serra E, Piccolomini R: Clinical and microbiological effects of subgingival administration of two active gels on persistent pockets of chronic periodontitis patients. *J Clin Periodontol* 2004;31:273–281.
- Reddy MS, Jeffcoat MK, Geurs NC, Palcanis KG, Weatherford TW, Traxler BM, Finkelman RD: Efficacy of controlled-release subgingival chlorhexidine to enhance periodontal regeneration. *J Periodontol* 2003;74: 411–419.
- Soskolne WA, Chajek T, Flashner M, Landau I, Stabholz A, Kolatch B, Lerner EI: An in vivo study of the chlorhexidine release profile of the PerioChip in the gingival crevicular fluid, plasma and urine. *J Clin Periodontol* 1998;25: 1017–1021.
- Soskolne WA, Heasman PA, Stabholz A, Smart GJ, Palmer M, Flashner M, Newman HN: Sustained local delivery of chlorhexidine in the treatment of periodontitis: a multi-center study. *J Periodontol* 1997;68: 32–38.
- Soskolne WA, Proskin HM, Stabholz A: Probing depth changes following 2 years of periodontal maintenance therapy including adjunctive controlled release of chlorhexidine. *J Periodontol* 2003;74:420–427.
- Stanley A, Wilson M, Newman HN: The in vitro effects of chlorhexidine on subgingival plaque bacteria. *J Clin Periodontol* 1989;16:259–264.

Reprint requests:

ZA Lutz Harnack
 Department of Periodontology
 Justus-Liebig University Giessen
 Schlangenzahl 14, 35392 Giessen
 Germany
 Fax: +49 641 9946189
 E-mail: Lutz.Harnack@dentist.med.uni-giessen.de