

# Chronic Periodontitis in Conjunction with Melkersson-Rosenthal Syndrome: A Case Report and Literature Review

Frank Bröseler, Angelika Neuber

**Background:** Melkersson-Rosenthal syndrome (MRS) is a very rare neurological disorder. The origin of MRS is as yet unknown. The diagnosis of the disease usually occurs in the patient's second or third decade of life. The clinical symptoms are remittent swellings of the oral, pharyngeal and laryngeal mucosa as well as the lips. Due to the presence of granulomata in all orofacial soft tissues, a plicated tongue as well as facial nerve paralysis may occur. Intermittent increase of mucosal swelling, including swelling of the gingiva, may increase the risk of development of chronic periodontitis by inhibiting local plaque removal.

**Case description:** This article describes a case of a patient with chronic periodontitis who had been diagnosed with MRS 14 years previously. Based on the clinical features, a protracted history and the histological findings from biopsies taken from the gingiva and palatal tissues a working diagnosis of MRS was made. The complex issues surrounding MRS as a diagnosis and its relationship to other oral granulomatoses are discussed in this paper.

**Conclusions:** Chronic inflammation not responding to initial periodontal therapy may indicate underlying systemic conditions, which have to be ruled out by clinical investigations, such as biopsy. Morphological change of the gingiva is one of the possible manifestations of MRS. Periodontitis with severe alveolar bone loss seems to be an entirely co-incidental finding. However, it is possible that alterations in gingival morphology, secondary to MRS, inhibit plaque removal and act as a local risk factor for periodontitis.

**Key words:** chronic periodontitis, Melkersson-Rosenthal Syndrome (MRS), Cheilitis granulomatosa, facial nerve paralysis, non-caseating epitheloid cell granuloma, oro-facial granulomatosis

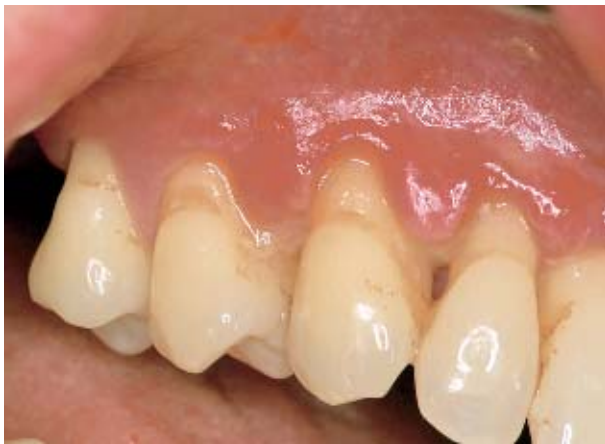## INTRODUCTION

Periodontal diseases can be secondary manifestations of systemic diseases, e.g. Papillon-Lefèvre syndrome.

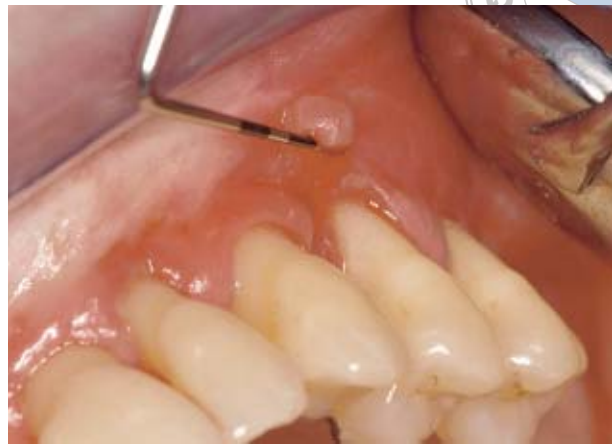Several publications have discussed the relationship of Melkersson-Rosenthal syndrome (MRS) to periodontal diseases (Graff-Radford, 1981; Hornstein, 1998; Littich et al, 2005; Rees, 1999; Worsaae et al, 1982; Worsaae and Pindborg, 1980; Zimmer et al, 1992). This clinical entity was first described by Melkersson in 1928 (Melkersson, 1928) as relapsing paralysis of the

facial nerve and oedema of the oral mucosa and the lips. In 1931, Rosenthal (Rosenthal, 1931) described the typical triad of the syndrome as facial nerve paralysis together with mucosal oedema and fissured tongue (*lingua plicata*).

The syndrome can be diagnosed even if the full triad is not present in a patient. Numerous variations of the clinical appearance have been described (Hornstein et al, 1987). There are mono-symptomatic and oligosymptomatic forms. The histological findings of non-caseating epitheloid cell granulomata in the oral connective tissues and nearby infiltrations of multinuclear giant cells may lead to



**Fig 1a** Typical gingival manifestation of MRS. Oedematous swelling like 'duplicated' papillae. Photograph of a 57-year-old female patient.



**Fig 1b** Typical gingival manifestation of MRS. Photograph of a 57-year-old female patient.

the diagnosis of MRS (Pindborg, 1993). In case of this histological finding in patients suspected of MRS, it is necessary to exclude other diseases like Crohn's disease, sarcoidosis, tuberculosis and angioedema (Cleary and Batsakis, 1996; Riggio et al, 1997; Leão et al, 2004).

MRS is a rare disease with an incidence of less than 0.1% among the general population (Ang and Jones, 2002). There are few statistics relating to it (Gottwald, 1981/1; Hornstein et al, 1987). The syndrome is usually first diagnosed in the patient's second (Worsaae et al, 1982) or third decade of life (Rees, 1999; Hornstein et al, 1987) but there are also descriptions of early onset in childhood (Worsaae et al, 1982) and adolescents (Hornstein et al, 1987). Facial paralysis, similar to Bell's palsy, as one of the major symptoms only occurs in a small percentage of affected patients (Rees, 1999; Hornstein, 1973; Hornstein et al, 1987) and the most common type seems to be the oligosymptomatic form associated with lip swellings similar to cheilitis granulomatosa (Eisenbud et al, 1971; Graff-Radford, 1981; Mesa et al, 1985). Women seem to be more susceptible than men. Zimmer et al (Zimmer et al, 1992) found a female/male ratio of 2:1 in an investigation of 42 patients, as Hornstein et al reported a ratio of 1.6:1 among 73 patients, whereas Worsaae and Christensen reported of 1.1:1 in a cohort of 33 patients.

Another differential diagnosis of MRS could be Miescher's cheilitis granulomatosa which is suggested as being an oligosymptomatic form of MRS

(Eisenbud et al, 1971; Gorlin et al, 1990; Worsaae et al, 1982; Worsaae and Pindborg, 1980) or even an orofacial manifestation of Crohn's disease (Cleary and Batsakis, 1996; Mesa et al, 1985; Scheper and Brand, 2002; Scully et al, 1982). The histopathologic findings of non-caseating granulomas and lymphocyte infiltrates in an oral manifestation of Crohn's disease are not distinguishable from the findings in MRS. Orofacial signs of Crohn's disease may appear even before intestinal involvement occurs (Scully et al, 1982; Leão et al, 2004). Worsaae et al (Worsaae et al, 1980) did not find any relationship to Crohn's disease in 16 investigated cases of complete MRS. However, as MRS patients commonly do not show the full symptomatic triad of the syndrome, the whole spectrum of conditions encompassed by the clinical term 'orofacial granulomatoses' (OFG) has to be considered (Alawi, 2005; Hornstein et al, 1987).

The typical gingival manifestations of MRS are mucosal swellings, tissue enlargement and inflammation (Rees, 1999; Worsaae and Pindborg, 1980; Zimmer et al, 1992). These features are caused by the oedema. The surface texture clinically demonstrates altered keratinisation (Rees, 1999; Pindborg, 1993; Littich et al, 2005). The interdental papillae sometimes show tissue proliferation and seem to have two component parts, with an interdental adherent inflammatory part and a vestibular floating part (Fig 1a and 1b).

The pathogenesis of the alveolar bone loss in MRS is more likely to be due to co-incidental chronic

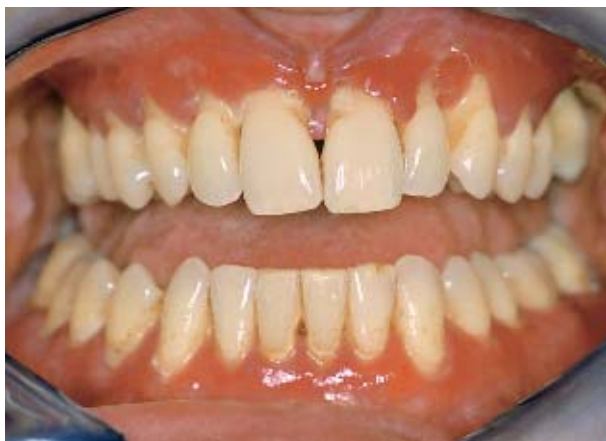

Fig 2a Clinical status at time of first examination.

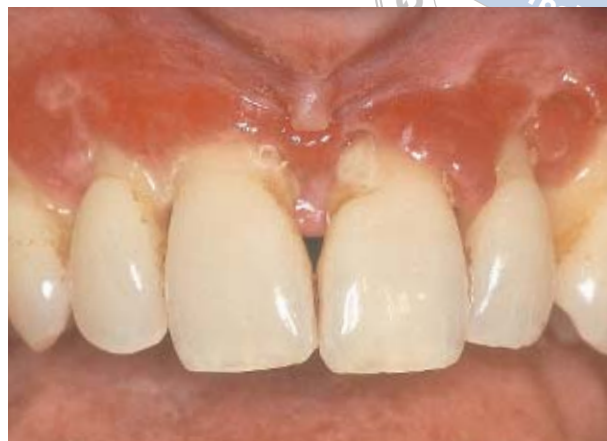

Fig 2b Clinical status - magnification.

periodontitis (CP). As a result of change in the gingival morphology there may be a higher risk of adhesion of bacterial plaque. Concomitant painful swellings of all oral mucosal tissues may also compromise the patient's oral hygiene.

## CASE DESCRIPTION AND RESULTS

A 57-year-old female patient was referred to our private periodontal practice in the spring of 2002. She had previously undergone four periodontal surgical procedures such as scaling and root planing, the most recent being in 1996. Clinically she revealed recurrent chronic periodontitis although she was receiving professional hygiene treatment at her general dentist's surgery every three months.

On her first visit to our surgery the patient was found to be in the early stages of an acute phase of the syndrome. MRS had first been clinically diagnosed in 1988, followed by histological examination of a laryngeal biopsy in the same year. Her vocal cords had been affected during each acute MRS episode.

Tuberculosis and sarcoidosis had been excluded in 1995. The clinical history made Crohn's disease an unlikely diagnosis, as there were no bowel symptoms so far, and her age at presentation did not fit with the reported peaks in occurrence of Crohn's disease. Thus, further extensive examinations such as colonoscopy or rectal biopsy were not deemed appropriate.

## Intraoral Clinical Findings

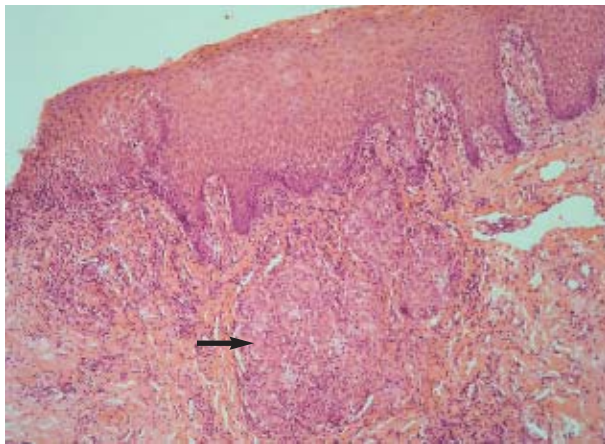
At the time of the first examination the gingivae showed partial necrosis of the surface of the marginal regions (Fig 2a and b). Generalised swelling and hypoplastic keratinisation of the gingiva was clinically present. The patient reported swelling in the laryngeal region with edematous thickening of the vocal cords and swelling of the upper lip. *Lingua plicata* was moderately present, whereas facial nerve paralysis was not and had not as yet occurred.

Previously, the patient had been referred to an oral surgeon for removal of tooth number 14 due to severe alveolar bone loss and tooth mobility. The remaining upper molars had a hopeless prognosis due to furcation involvement and mobility. The radiological examination revealed generalised alveolar bone loss with only few local vertical defects.

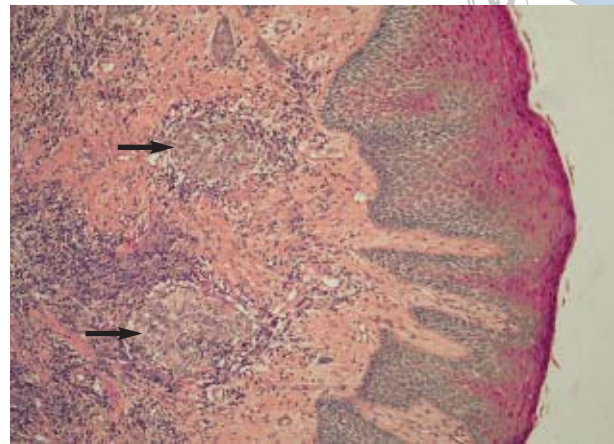
## Histological Findings

Biopsy specimens of the intra-oral tissues were taken from the dorsal region of the palate and from the attached gingiva belonging to the papilla mesial to the first upper bicuspid (number 5). The histological findings were consistent with those noted in 1988: non-caseating epitheloid cell granuloma and aggregations of multinuclear giant cells could be seen (Figs 3–5).

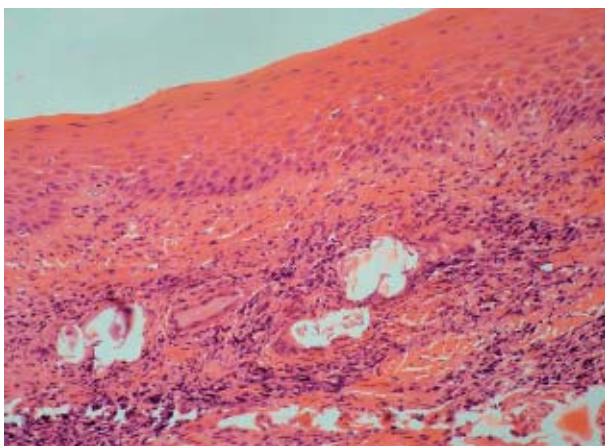
Beneath an irregular hyperplastic squamous epithelium there was a well defined non-caseating epitheloid cell granuloma with few multinucleate giant cells. The connective tissue showed moderate oedema with few to moderate numbers of infiltrating mononuclear cells.



**Fig 3** Gingiva from tooth number 5, non-caseating granuloma.



**Fig 4** Specimen from palatal mucosa. Irregularly enlarged squamous epithelium; well-defined sub epithelial epithelioid cell granuloma without necroses; moderate lymphocyte infiltrations. Staining: paraaminosalicylic acid, original magnification x50.



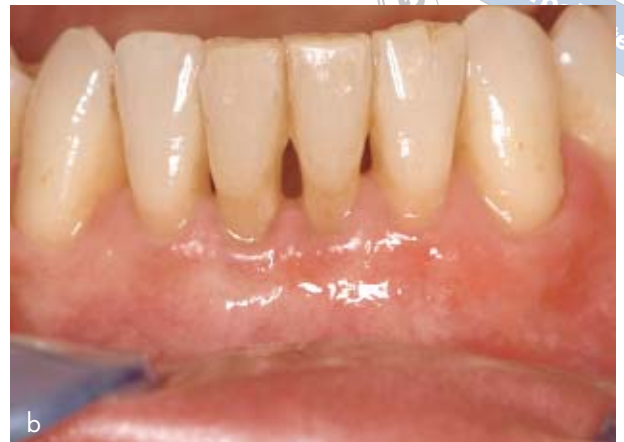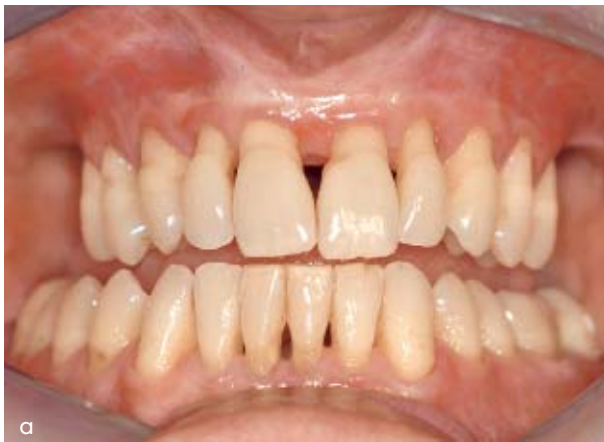**Fig 5** Palatal mucosa. Enlarged squamous epithelium; epithelioid cell granuloma without necroses in the connective tissue. Fibrosis of the lamina propria with deposits of dystrophic calcification typical of long standing lesions. Staining: HE, original magnification x50.

## DISCUSSION

This case report describing Melkersson-Rosenthal syndrome in a 57-year-old caucasian female patient shows that chronic periodontitis (CP) may arise in conjunction with the syndrome. This is a finding previously reported in several papers (Clayden et al, 1997; Graff-Radford, 1981; Hornstein, 1973; Mesa et al, 1985; Rees, 1999; Pindborg, 1993; Worsaae et al, 1982; Worsaae and Pindborg, 1980; Zimmer et al, 1992; Hornstein et al, 1987), but seems likely to

be coincidental or due to local compromise in plaque removal due to the gingival enlargement. MRS is mostly diagnosed in an incomplete form of the classical triad (Worsaae and Pindborg, 1980; Hornstein et al, 1987). Gingival lesions only occur in a smaller group of MRS patients (Worsaae and Pindborg, 1980; Zimmer et al, 1992; Littich et al, 2005). Our patient did not show the complete triad of the syndrome as facial nerve paralysis never occurred. A differential diagnosis of Miescher's cheilitis granulomatosa, sarcoidosis (Boeck), tuberculosis and an oral manifestation of Crohn's disease had been ruled out (Buser and Burkhardt, 1985; Serrat Soto et al, 1997).

Consistent with several reports of gingival features in MRS (Gottwald, 1981/1; Mesa et al, 1985; Zimmer et al, 1992), our patient showed the typically swollen papillae due to aggregations of subepithelial granulomata and oedema. Histological features of MRS were evident in biopsy samples. There is evidence that the morphological changes of the gingiva are one of the manifestations of MRS (Clayden et al, 1997; Gottwald, 1981/1; Nally, 1970; Rees, 1999; Pindborg, 1993). Periodontitis with severe alveolar bone loss seems to be a secondary phenomenon. Indeed, it has not been reported to have been found in children or young adults with MRS. Periodontitis may result as a secondary complication due to plaque accumulation around the untreated gingival enlargement in MRS. The case presented here supports this assumption because



**Fig 6a–c** Clinical status two years after surgical therapy. Slight swellings of oral mucosa. Gingiva generally attached to the root surfaces, gingival margins free of inflammation signs. Maxilla: note incision line resulting from double split preparation at mucogingival junction.

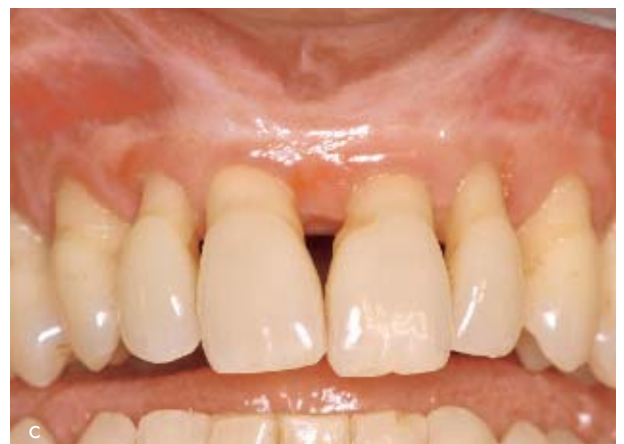the type of horizontal bone loss found was strictly related to chronic periodontitis.

Various forms of therapy have been described for MRS. Systemic corticosteroid therapy has been reported to decrease inflammation in MRS patients (Rees, 1999; Zimmer et al, 1992; Littich et al, 2005). Eisenbud (Eisenbud et al, 1971) reported on the successful treatment of lip swelling (cheilitis granulomatosa, incomplete MRS) through the local injection of triamcinolone acetonide over a one-year period. Krutchkoff (Krutchkoff and James, 1978) described a surgical cheiloplasty treatment combined with triamcinolone acetonide injections, in one case of monosymptomatic MRS.

'Removal of odontogenic foci' was beneficial for patients' comfort in a few cases, reported by Worsaae (Worsaae et al, 1982). Another patient had been treated by the removal of all his teeth (Worsaae et al, 1982). Worsaae and Pindborg (Worsaae and Pindborg, 1980) reported on one patient whose gingival features had been treated by repeated gingivectomies, but further pocket formation could not be avoided.

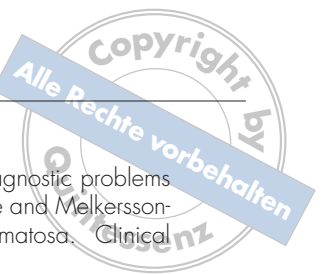In a case described by Takeshita et al in 1995, the swelling of the lips and of the buccal mucosa next to a periodontally affected lower first molar decreased two months after the removal of that tooth. Antibiotics and anti-inflammatory drugs had been administered concomitantly.

Our patient underwent systematic periodontal treatment including open flap surgery. A modification of an apically repositioned flap design re-



ported by Carnevale and Kaldahl (Carnevale and Kaldahl, 2000) resulted in uncomplicated wound healing. As the patient is now able to perform adequate levels of individual oral hygiene, the progression of bone loss was stopped over a three-year period postoperatively. The long-term prognosis is good, provided the patient remains on a supportive care program. Corticosteroids were administered by her physician during a temporary progression of the symptoms of MRS one year postoperatively.

This case report has highlighted the complexities of assigning a definitive diagnosis of MRS, given the similarities in histology with other oro-facial granulomatoses. Indeed, the diagnosis was arrived at because the patient developed no signs of intestinal Crohn's disease and it was therefore a diagnosis by exclusion. The importance of creating a dento-gingival complex conducive to home care was essential in achieving a successful outcome to the periodontal management in the reported case.



## REFERENCES

- Alawi F. Granulomatous diseases of the oral tissues: differential diagnosis and update. *Dent Clin North Am* 2005; 49:203–221.
- Ang KL, Jones NS. Melkersson-Rosenthal syndrome. *J Laryngol Otol* 2002;116: 386–388.
- Armstrong C, Napier S, Linden GJ. Sarcoidosis with gingival involvement: a case report. *J Periodontol* 2004;75: 4,608–612.
- Balevi B. Melkersson-Rosenthal syndrome: Review of the literature and case-report of a 10-year misdiagnosis. *Quintessenz Int* 1997;28:265–269.
- Buser D, Burkhardt A. Sarcoidosis of the oral mucosa. Case report, literature review and differential diagnosis. *Dtsch Z Mund Kiefer Gesichtschir.* 1985;9:4,284–291.
- Carnevale G, Kaldahl WB. Osseous resective surgery. *Periodontology* 2000; 2000;22:59–87.
- Clayden AM, Bleys CM, Jones SF, Savage NW, Aldred MJ. Orofacial granulomatosis: A diagnostic problem for the unwary and a management dilemma. Case reports. *Australian Dental Journal* 1997;42/4:228–232.
- Cleary KR, Batsakis JG. Orofacial granulomatosis and Crohn's disease. *Ann Otol Rhinol Laryngol* 1996;105: 2,166–167.
- Eisenbud L, Hymowitz S, Shapiro R. Cheilitis Granulomatosa. *Oral Surg* 1971; 32/3:384–389.
- Gorlin RJ, Cohen MM, Levin LS. Syndromes with gingival/periodontal components. In: *Syndromes of the Head and Neck.* New York: Oxford University Press, 1964/1990;847–858.
- Gottwald W. Melkersson-Rosenthal Syndrom: Teil 1: Klinisches Bild, Diagnose. *Fortschritte der Medizin* 1981; 99/8:249–252.
- Gottwald W. Melkersson-Rosenthal Syndrom: Teil 2: Diagnose (Forts.), Differentialdiagnose, Verlauf, Prognose, Neuropathologie, Therapie. *Fortschritte der Medizin* 1981;99/10:326–330.
- Graff-Radford SB. Melkersson-Rosenthal syndrome. A review of the literature and case report. *S Afr Med J* 1981; 60:7174.
- Hornstein OP, Stosiek N, Schönberger A, Meisel-Stosiek M. Klassifikation und klinische Variationsbreite des Melkersson-Rosenthal-Syndroms (MRS). *Z. Hautkr.* 1987; 62:20,1453–1475.
- Hornstein OP. Glossitis granulomatosa – ein ungewöhnlicher Subtyp des Melkersson-Rosenthal-Syndroms. *Mund-Kiefer-GesichtsChir* 1998;2:14–19.
- Hornstein OP. Melkersson-Rosenthal Syndrome: a neuro-muco-cutaneous disease of complex origin. *Current Probl Dermatol* 1973;5:117.
- Krutchkoff D, James R. Cheilitis granulomatosa: successful treatment with combined local triamcinolone injections and surgery. *Arch Dermatol* 1978;114:1203–1206.
- Leão JC, Hodgson T, Scully C, Porter, S. Review article: oro-facial granulomatosis. *Alimentary Pharmacology & Therapeutics* 2004;20:1019–1027.
- Littich M, Effenberger S, von den Driesch P, Platzer U. Gingivawucherung als intraorale Manifestation des Melkersson-Rosenthal-Syndroms. *Parodontologie* 2005; 16/1:51–58.
- Melkersson E. Ett fall av recidiverande facialis pares i samband med angioneurotisk ödem. *Hygiea* 90:1928; 737–741.
- Mesa M, Zhu Y, Worsaae N, Reibel J. Diagnostic problems between oral lesions of Crohn's disease and Melkersson-Rosenthal syndrome/cheilitis granulomatosa. *Clinical Preventive Dentistry* 1985;7/1:23–25
- Nally FF. Melkersson-Rosenthal Syndrome. *Oral Surg* 1970; 29:5,694–703.
- Pindborg JJ. *Farbatlas der Mundschleimhautrekrankungen.* Köln: Dt. Ärzte-Verlag, 1993.
- Rees TD. Melkersson-Rosenthal syndrome and cheilitis granulomatosa. In: *orofacial granulomatosis and related conditions.* *Periodontology* 2000 1999; 21:145–157.
- Riggio MP, Gibson J, Lennon A, Wray D, MacDonald DG. Search for mycobacterium paratuberculosis DNA in orofacial granulomatosis and oral Crohn's disease tissue by polymerase chain reaction. *Gut* 1997;41:646–650.
- Rosenthal C. Gemeinsames Auftreten von (rezidivierender familiärer) Facialislähmung, angioneurotischem Gesichtödem und Lingua Plicata in Arthritis-Familien. *Zentralbl ges Neurol. Psychol* 1931;131:475–480.
- Scheper HJ, Brand HS. Oral aspects of Crohn's disease. *Int Dent J.* 2002;52:3, 163–172.
- Serrat Soto A, Lobo Valentin P, Redondo Gonzalez LM, Sanz Santa Cruz C, Verrier Hernandez A. Oral sarcoidosis with tongue involvement. *Oral Surg Oral Med Oral Pathol Oral Radiol Endod* 1997;83:6,668–671.
- Scully C, Cochran KM, Russell RI, Ferguson MM, Ghouri MAK, Lee FD, MacDonald DG, McIntyre PB. Crohn's disease of the mouth: an indicator of intestinal involvement. *Gut* 1982;23:198-201.
- Takeshita T, Koga T, Yashima Y. Case report: Cheilitis granulomatosa with periodontitis. *Dermatol* 1995;22: 804–806.
- van der Velden U. Regeneration of the interdental soft tissues following denudation procedures. *J Clin Periodontol* 1982;9:6,455-459.
- Wiesenfeld D, Ferguson MM, Mitchell DN, MacDonald DG, Scully C, Cochran K, Russel RI. Oro-facial granulomatosis - a clinical and pathological analysis. *Q J Med* 1985;54:101–113.
- Worsaae N, Christensen KC, Bondesen S, Jarnum S. Melkersson-Rosenthal syndrome and Crohn's disease. *Br J Oral Surg* 1980;18:3,254–258.
- Worsaae N, Christensen KC, Schildt M, Reibel J. Melkersson-Rosenthal Syndrome and cheilitis granulomatosa - A clinicopathologic study of thirty-three patients with special reference to their oral lesions. *Oral Surg Oral Med Oral Pathol* 1982;54/4:404–413.
- Worsaae N, Pindborg JJ. Granulomatous Gingival Manifestations of Melkersson-Rosenthal Syndrome. *Oral Surg Oral Med Oral Pathol* 1980;49:131–138.
- Zimmer WM, Rogers RS III, Reeve CM, Sheridan PJ. Orofacial manifestation of Melkersson-Rosenthal syndrome. *Oral Surg Oral Med Oral Pathol* 1992;74: 610–619.

## Reprint requests:

Dr. Frank Bröseler  
Krefelder Str. 89  
52070 Aachen, Germany  
Tel: +49-241-918450  
Fax: +49-241-9184521  
E-mail: praxis@paro-aachen.de